

# *Cartilage spreader grafting for lateral augmentation of the middle third of the nose*

H.D. VUYK M.D., P.H.D.  
*Department of Otolaryngology  
Facial Plastic and Reconstructive Surgery  
Gooi Noord Hospital  
Blaricum - The Netherlands*

## **Summary**

Surgery of the middle third of the nose is one of the challenges in rhinoplasty. The middle nasal third is of the utmost functional importance, as it corresponds to the smallest cross-sectional area of the whole respiratory tract, the nasal valve. Aesthetically, the middle nasal third should be an inconspicuous part of the nose, characterized by appropriate width.

There exists a plethora of surgical techniques to correct functional and aesthetic problems of the middle nasal third, testifying to the difficulties involved. In a series of 74 patients, we have used cartilaginous autograft to widen the middle nasal third for both functional and aesthetic reasons. The open approach was used as it offers improved surgical control of this technique, compared to the endonasal approach.

Functional improvement rate was 85% after a mean follow-up of 8 months. For aesthetic purposes, spreader grafts were successfully used to reconstruct the cartilage dorsal width after hump removal as well as for correction of asymmetries. Considering our functional success rate and the aesthetic possibilities of the technique, we think cartilage spreader grafting has distinct advantages over previous methods. This technique may indeed be a straightforward solution for both functional and aesthetic problems of the middle third of the nose. The open approach will probably bring this technique within reach of many rhinoplastic surgeons.

*Keywords:* Nasal valve, septum, lateral wall, spreader graft

## **Introduction**

Surgery of the middle third of the nose is one of the challenges in rhinoplasty. The middle third of the

*Correspondence to:* Dr. H.D. Vuyk, Department of Otolaryngology, Facial Plastic and Reconstructive Surgery, Gooi Noord Hospital, Rijksstraatweg 1, 1261 AN Blaricum, The Netherlands.

nose is of the utmost functional importance as it corresponds to the smallest cross-sectional area of the whole respiratory tract, the nasal valve (NV) [1]. Any alteration in structure or diameter of this region may

cause nasal obstruction [2]. Despite a series of excellent articles [3, 4, 5, 6, 7] the exact function of

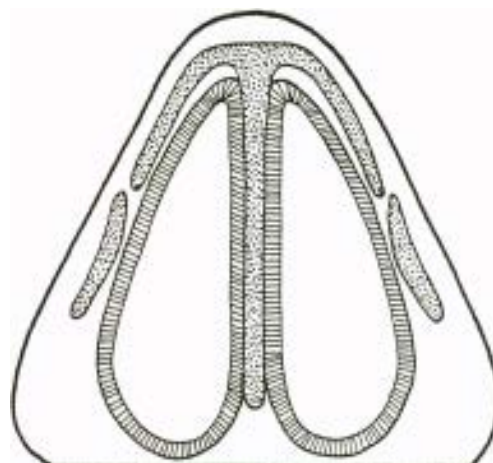
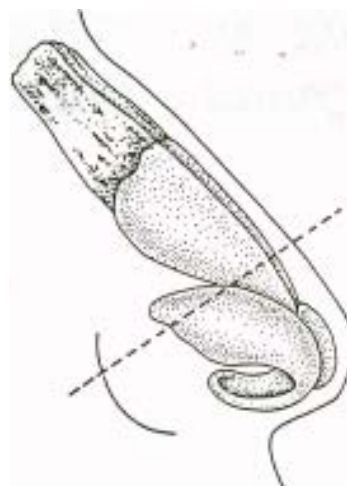
the middle nasal third, which is known to act as a valve during inspiration, remains uncertain [8, 9]. From an aesthetic point of view, a pinched appearance of the middle nasal third may be a particularly unattractive feature, in need of surgical correction. There exists a plethora of surgical techniques to correct functional and aesthetic problems of the middle third of the nose, thus testifying to the difficulties involved. Most functional techniques aim either to increase the rigidity of the lateral nasal wall [9, 10] or to increase the area of the nasal valve [11]. Techniques have been described to widen the middle nasal third [12, 13, 10] for aesthetic reasons.

Sheen (1984) [12] has simplified earlier techniques by using cartilage grafts to push the upper lateral cartilage away from the septum. This « spreader grafting » technique, which increases the area of the NV and widens the middle nasal third at the same time, may be used for both functional and aesthetic reasons. The limited exposure of the closed (endonasal) approach, as suggested by Sheen, has prevented general understanding and application of this grafting technique. The open approach, has brought more insight in surgical anatomy [14] and technical possibilities have increased enormously [13, 15].

This article concerns a series of 74 patients in whom cartilage spreader grafts were used for lateral augmentation of the middle third of the nose, using the open rhinoplasty approach. The operation was performed for functional or aesthetic problems or a combination of both. Anatomy, physiology, and pathophysiology of the nasal valve (NV) will be briefly reviewed. Methods of evaluation and prevention of middle nasal third problems will be suggested. The surgical technique of cartilage spreader grafting, used in this series, will be described and results will be discussed.

### Anatomy

The nasal valve (NV) is defined as the region of the nasal airway bounded by the caudal end of the upper lateral cartilage (ULC), the nasal septum and the pyriform aperture (Figures 1 a, b). The NV has the smallest cross-sectional area of the entire respiratory tract, which ranges from 55 mm [4] to 64 mm [16] in caucasians. The NV area in Negroes is larger compared to caucasians.



**Figures 1 a, b**

- a Anatomie location of nasal valve (NV). NV is bounded by caudal end of upper lateral cartilage and septum.
- b The angle between the upper lateral cartilage (ULC) and the septum (NV) is normally 10-25 degrees.

The NV angle is measured in degrees and represents the angle between the ULC and the nasal septum which normally ranges from 10 to 15 degrees.

### Physiology

The complete function of the NV remains uncertain. During inspiration a pressure gradient is established between the lungs, the nasopharynx, the internal

nose and the atmosphere. The pressure difference between the internal nose and the atmosphere results in a force which tends to depress the flexible cartilaginous part of the nose inward. During normal inspiration the patency of the NV is maintained by the structural rigidity of the lateral nasal wall (LNW) together with alar dilator muscle activity [8, 5]. With rapid or deep nasal breathing, such as during exercise, some inward collapse of the cartilage normally occurs during inspiration, narrowing the airway in the upper half of the NV. The significance of this slight collapse is not clear [8, 9]. However, if the NV collapses during quiet normal breathing, nasal obstruction will be clinically significant.

### Pathophysiology

Two main reasons for nasal valve insufficiency and subsequent collapse during normal breathing, are narrowing of the NV area or loss of support of the LNW (upper and/or lower lateral cartilage) or a combination of both [9]. Narrowing of the NV area will result in decreased airflow. To increase the insufficient airflow, the negative pressure in the nasopharynx and internal nose is increased. Thus, the pressure gradient between the atmosphere and the internal nose will increase inducing a suction effect which draws the ULC onto the nasal septum. Subsequently, the NV area will be narrowed furthermore. Inadequate support of the cartilaginous nasal wall is most commonly seen after excessive rhinoplastic surgery. Cases of weak ULC or LLC unrelated to previous surgery or trauma are rare. As the dilator muscle of the nose contributes to the rigidity of the NV, facial palsy may sometimes lead to NV insufficiency [17].

The NV area may be altered by septal, ULC or mucosal problems as well as by scarring [8]. Septal deviation, sometimes in combination with a twisted nose, is certainly the most common offender causing NV insufficiency. If the septum is too high, the ULC are pushed up and deflected towards the septum, resulting in an acute NV angle inferior to 10 degrees. This condition has often been called « a tension nose ».

It has been shown that the mucosa of the inferior turbinate may contribute significantly to the airflow resistance of the NV by altering the NV area [5]. This is especially true in the negroid nose.

Some obstructing deformities outside the NV area, such as posterior septal deviation and inferior turbinate enlargement, may be the cause of NV insufficiency. Because of the increased resistance to airflow produced by the obstruction, the patient takes a deeper breath, causing increased negative pressure in the back of the nose and thus increasing the resulting pressure gradient. This increased negative pressure will increase airflow but will also tend to collapse the NV, even if normal. For the same physiological reasons an extremely wide columella may cause NV insufficiency well. NV insufficiency that occurs only during deep breathing, such as in exercise, must be considered partially physiological so treatment is usually not indicated [9].

### Evaluation

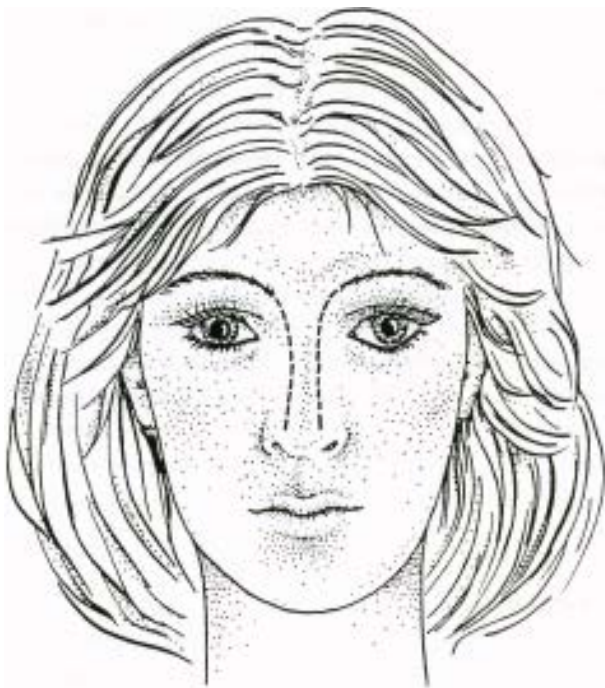The proper treatment of NV insufficiency depends on a correct diagnosis of the cause of the insufficiency. NV insufficiency is not common. The diagnosis is difficult and should be made with care. Case history of previous trauma or rhinoplastic surgery is important.

The NV is perhaps best examined without a nasal speculum because the instrument may distort the relationship between the caudal end of the ULC and the septum. A nasal endoscope is ideal for direct examination of this important airflow region at rest and during breathing. The mucosal status of the inferior turbinate should be assessed. A valuable and simple clinical test used to confirm abnormality of the nasal valve consists of supporting the lateral nasal wall and/or opening the NV angle with a fine metal probe. Rhinomanometry may contribute to the evaluation of NV insufficiency as well [7].

Aesthetically, the middle nasal third is the mid section of an integrated form, defined by smooth, slightly curved, divergent lines that flow from the root of the nose to the tip [12]. Ideally, these lines are curved upward laterally and blend in with the eyebrow (Figure 2). A very narrow middle nasal third or a regional asymmetry may indeed be unattractive.

### Prevention

The usual cause of reduced NV support is loss of vestibular skin, loss of ULC and LLC or both after rhinoplasty. In this respect, the best treatment is



**Figure 2**  
Frontal view, showing the dorsal radix-dome line, which blends into the browline. Breaking of this line distorts the midnose contour.

prevention during rhinoplasty. Adamson (1990) [18] has shown that cosmetic rhinoplasty need not result in subjective or objective nasal obstruction if surgery is performed correctly.

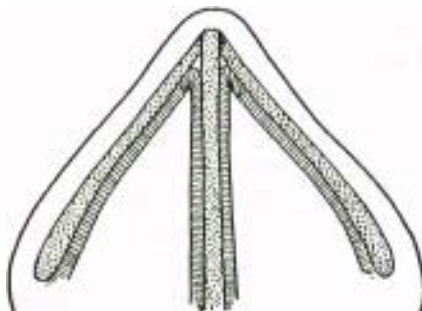
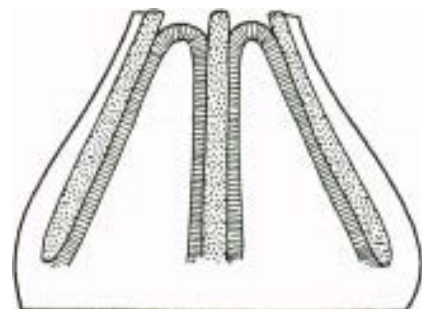
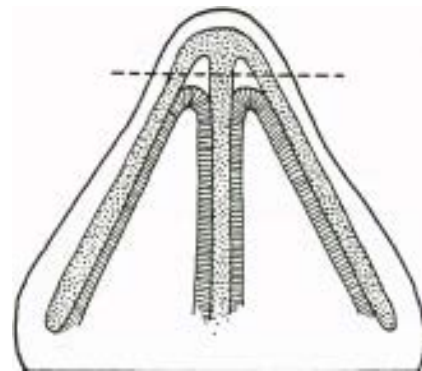
If an intercartilaginous incision is extended anteriorly to join a columella transfixion incision, some scar contraction occurs. This scar contraction will blunt the NV angle and reduce the NV area [19]. In contrast to the endonasal approach, the incisions used in the external transcolumella approach will not, alone, cause NV insufficiency.

Modern rhinoplasty relies on conservation, rearrangement and augmentation rather than reduction. By adhering to these modern principles, NV insufficiency can be prevented. In other words, vestibular skin must be preserved and cartilage excisions limited.

However, reduction of the nasal dorsum may still put the patient at risk of NV insufficiency. By removing the cartilaginous hump, the width of the middle nasal third, being the roof of the NV area, is reduced. In other words, a T-shaped dorsal septal edge is converted to a thinner I-shaped structure, with subsequent reduction of the NV angle and NV area (Figures 3 a, b, c). Patients with short nasal bones

deserve special attention in this respect. If the ULC is detached from the septum in these patients, it will lack support and collapse. The collapsed ULC must at least be sutured to the supporting dorsal edge of the septum to reapproximate the original T-frame structure. Better, still the width of the roof of the NV area should be reconstituted as part of the rhinoplasty procedure using cartilage grafts [12, 13].

This especially holds true in case of short nasal bone, long upper lateral cartilages and after excessive hump removal.



**Figures 3 a, b, c**  
a The dorsal septal edge is continuous with the upper lateral cartilages on both sides, usually resulting in a T-shaped configuration.  
b Resection of the roof of the nose may result in an I-shaped configuration with subsequent loss of the nasal valve area (c).

## Treatment

Treatment of the NV insufficiency basically aims to increase support of the lateral nasal wall and/or increase the NV area.

### *Increasing support*

Bone or cartilage autografts in the area of the NV can be used to increase rigidity of the lateral nasal wall. However, the bulk of tissue itself may reduce the NV area, leading to uncertain results. The main indication for cartilage onlay batten may be strengthening of the LLC which has previously been over-resected [9, 10].

Rotation of the LLC as a method for strengthening the support of the LNW is described by Farrion [20] and Rettinger [21]. The rotation technique is indicated if a strong LLC threatens the NV area by protruding in the vestibule. However, we feel upward rotation of the LLC may result in supratip fullness and alar rim retraction.

### *Widening of the NV area*

Often the NV area can be increased by correction of a septal deflection. In cases of hypertrophy of the head of the inferior turbinate, the NV area may be enlarged by resection of the head of the offending turbinate. Various methods have been described to widen NV area by pushing the upper lateral cartilage outward at the apex of the NV area. One of the techniques [22, 23] is in essence a Z-plasty with transposition of a cephalic portion of the lower lateral cartilage, including mucosal lining, between the septum and the severed upper lateral cartilage. The technique is difficult and has various other disadvantages, which have precluded general acceptance.

As early as 1969, Walter [11] described a method for increasing a too acute nasal valve angle. A composite skin-cartilage graft was placed between the severed upper lateral cartilage and the septum. This graft holds the upper lateral cartilage away from the midline. In essence the graft increase not only the angle of the nasal valve, but also the NVA. This concept was simplified and popularised by Sheen [12, 19] for aesthetic purposes. Sheen propagated the use of cartilage grafts without skin to reconstruct the middle nasal vault.

## Cartilage spreader grafting technique

### *Approach*

Sheen [12] used an endonasal approach for placement of the graft. We think the external approach offers better exposure with improved surgical control of the manoeuvres compared to the endonasal approach [2, 13, 25]. Moreover, incisions are kept away from the NV. The columellar scar is not a reasonable argument against this approach [26].

### *Grafting material*

Autogenous cartilage grafting material has distinct advantages over other grafting materials for nasal reconstruction because of its superior long-term survival rates, its easy availability in the head and neck region and because of the low risk of infection and resorption when implanted in the nose [10]. Septal cartilage is ideal for grafting the middle nasal vault owing to its flat shape and stiffness. However, ear cartilage or sometimes the cephalic portion of the lower lateral cartilage may also be used.

### *Graft Sculpturing*

The preoperative situation dictates the length and thickness of the graft. A flat rectangular piece of cartilage is used, averaging 2 to 2.5 cm in length, 3 to 5 mm in width and 2 to 3 mm in thickness (usual septal thickness). The graft may extend partially or completely along the length of the upper lateral cartilage. In case of nasal bone collapse the graft may even extend into the bony nasal pyramid. A graft wider than 5 mm would add too much bulk to the septum and theoretically compromise the nasal valve area. Depending on the situation, the thickness of the graft will vary. In functional rhinoplasty grafts will generally be chosen thicker than for purely cosmetic applications. We have used double layer grafts with a thickness of up to 4 mm for functional reasons mainly. Widening of the middle nasal third is to be anticipated with these spreader grafts. Although this widening may be a trade-off from a purely functional stand point, widening may be just the desired cosmetic effect. For example, a slight concavity on one side causing cosmetic problems, can be corrected using a spreader graft only.



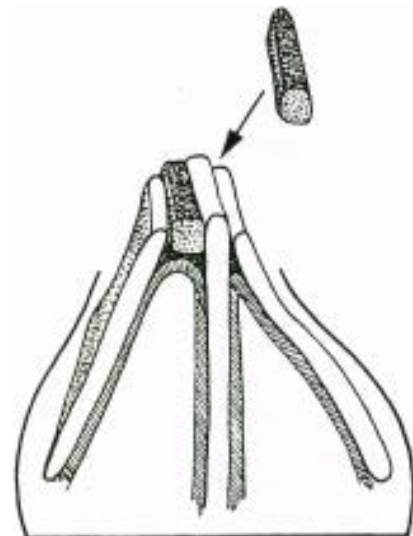
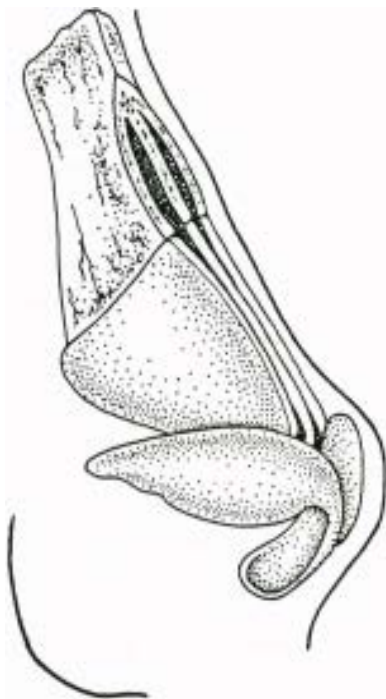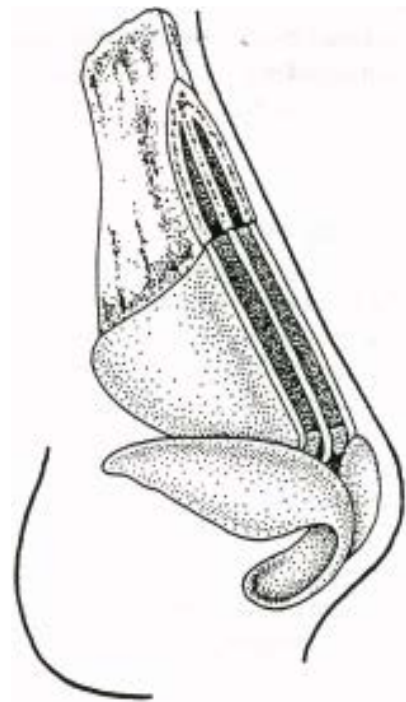
If used on both sides, it is important that the grafts be equal in width to provide symmetrical lateral spreading of the walls.

**Grafting**

The ULC (or remnants of it) is freed from the septum by dissection in a subperichondrial plane. The subperichondrial dissection is limited to 3-5 mm below the dorsal edge of the septum (the width of the graft), to prevent the graft from falling into the nasal cavity.

In cases of collapsed nasal bone, a pocket is made high up under the bony nasal dorsum. After medial and lateral osteotomies with outfracturing of the collapsed nasal bone the graft is placed extending into the bony nasal pyramid.

The graft is glued or sutured to either side of the septum. The ULC are then sutured in a mattress type fashion to the newly formed dorsal septal edge (Figures 4 a, b, c).



**Figures 4 a, b, c**  
 a A pinched middle third of the nose. b Bilateral spreader grafts used of lateral augmentation. c Curved cartilage fixed between upper lateral cartilage and dorsal nasal septum.

**Patiëntmaterial**

From 1989 to the end of 1992 a total of 280 patients underwent rhinoplasty performed by the author. In 74 of these patients spreader grafts were used. Four of these patients were lost to follow up. The group consisted of 47 male and 27 female patients, age

varying from 17 to 57 years with a mean age of 34 years. Seventeen of these patients had undergone previous nasal surgery. Two of the 8 previous septoplasties and 1 of the 9 previous rhinoplasties had been performed by the author himself.

In all but 1 of the 74 patients evaluated an external approach was used. The procedure was performed under general or local anaesthesia with sedation, using antibiotic prophylaxis. Spreader grafts were used on one side in 26 patients and on both sides in 42 patients. A total of 110 sides could be evaluated. On 24 sides the grafts were used for purely functional reasons and on 25 sides for cosmetic reasons only. On 61 sides grafting was performed for both functional and aesthetic reasons.

Septal cartilage was used in nearly every case. On 13 sides ear cartilage was used and on 4 sides pieces of the superior border of the LLC was grafted. In 5 patients part of the cartilaginous hump was used as a spreader graft. A double layer graft was used on 13 sides. On 5 sides the grafts reached up into the bony nasal vault. Various adjunctive procedures were performed at the time of the surgery aiming to improve functional problems (Table 1).

Our follow-up ranges from 2 to 36 months, mean 8 months.

**Table 1**  
Adjunctive rhinoplasty procedures in 52 patients treated for functional problems

septal surgery	49
conchal reduction	59*
onlay lateral nasal wall	16*
ethmoidectomy	9*
columnella narrowing	6
lower lateral cartilage rotation	2*
outfracture	4*
twisted nose correction	10
septal perforation closure	1

\* number of sites is given

## Results

### *Functional results*

Functional results were evaluated subjectively by the patients. Nasal airway obstruction was said to be improved in 73 of a total of 85 sides in which spreader grafts were used for functional problems. On 12 sides the airway obstruction remained unchanged. Initial obstruction was never increased post-operatively.

The functional improvement rate was 86 %. In three sides (2 patients) function was improved after subsequent ethmoidectomy combined with conchal reduction. In one of these 3 sides a relatively long spreader graft which reached into the vestibule was shortened. In one patient a cartilaginous alar batten was used to stiffen both nasal side walls.

### *Aesthetic results*

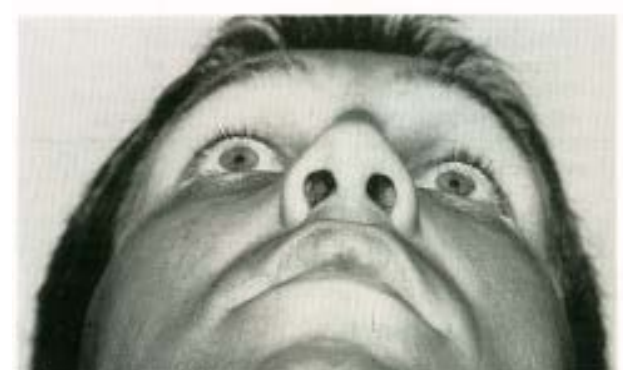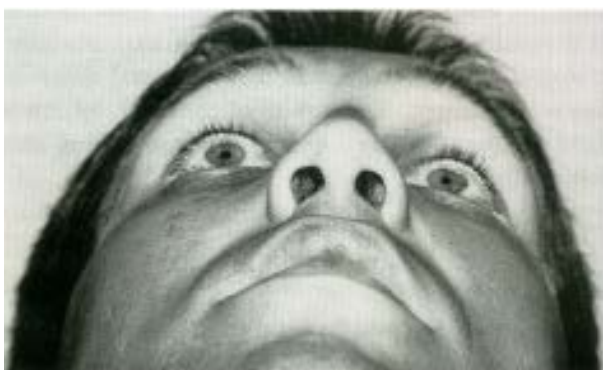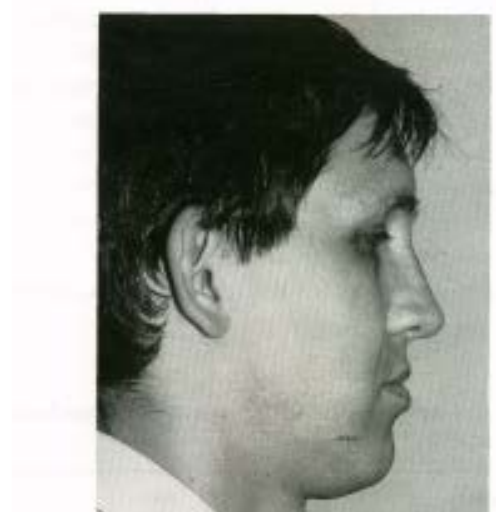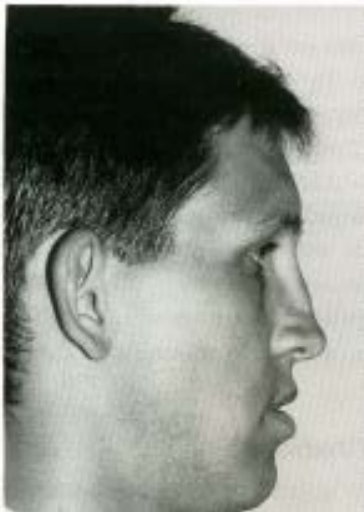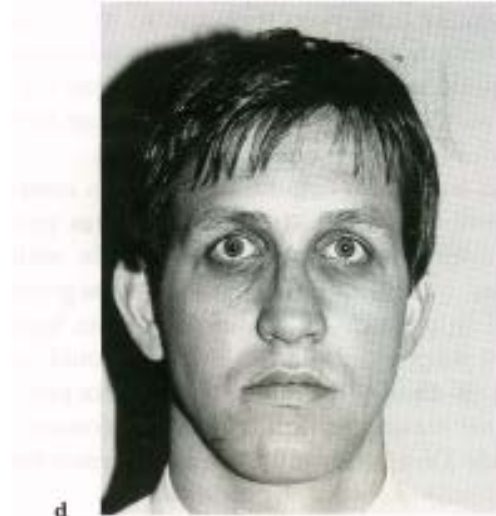Spreader grafts were used on 86 sides to obtain some broadening of the middle nasal third. Aesthetic results are very difficult to quantify but undercorrection could be noticed in a few patients. Overcorrection was very rare indeed. One of our patients complained of a too broad middle nasal third and considers revision surgery. The great majority of our patients are satisfied with the aesthetic improvement achieved by the spreader grafts as part of the rhinoplasty procedure. Figures 5, 6, and 7 illustrate some of the indications and are representative of the results in this series. When grafts were used for purely functional reasons a fullness in the middle nasal third was not especially desirable and might have been objectionable. However, all of these "purely functional" patients were satisfied with the compromise between optimal breathing and cosmetic result.

### *Complications*

All grafts appear to have been adequately fixed as no displacement was observed. In one patient a septal abscess occurred 4 months after the surgery. This infection was ill explained. Apart from some flatness of the middle nasal third dorsum when extreme lateral augmentation was aimed for, no dorsal deformities were created. Resorption of cartilage, which is hard to quantify, could not be noted during this follow-up period.

## Discussion

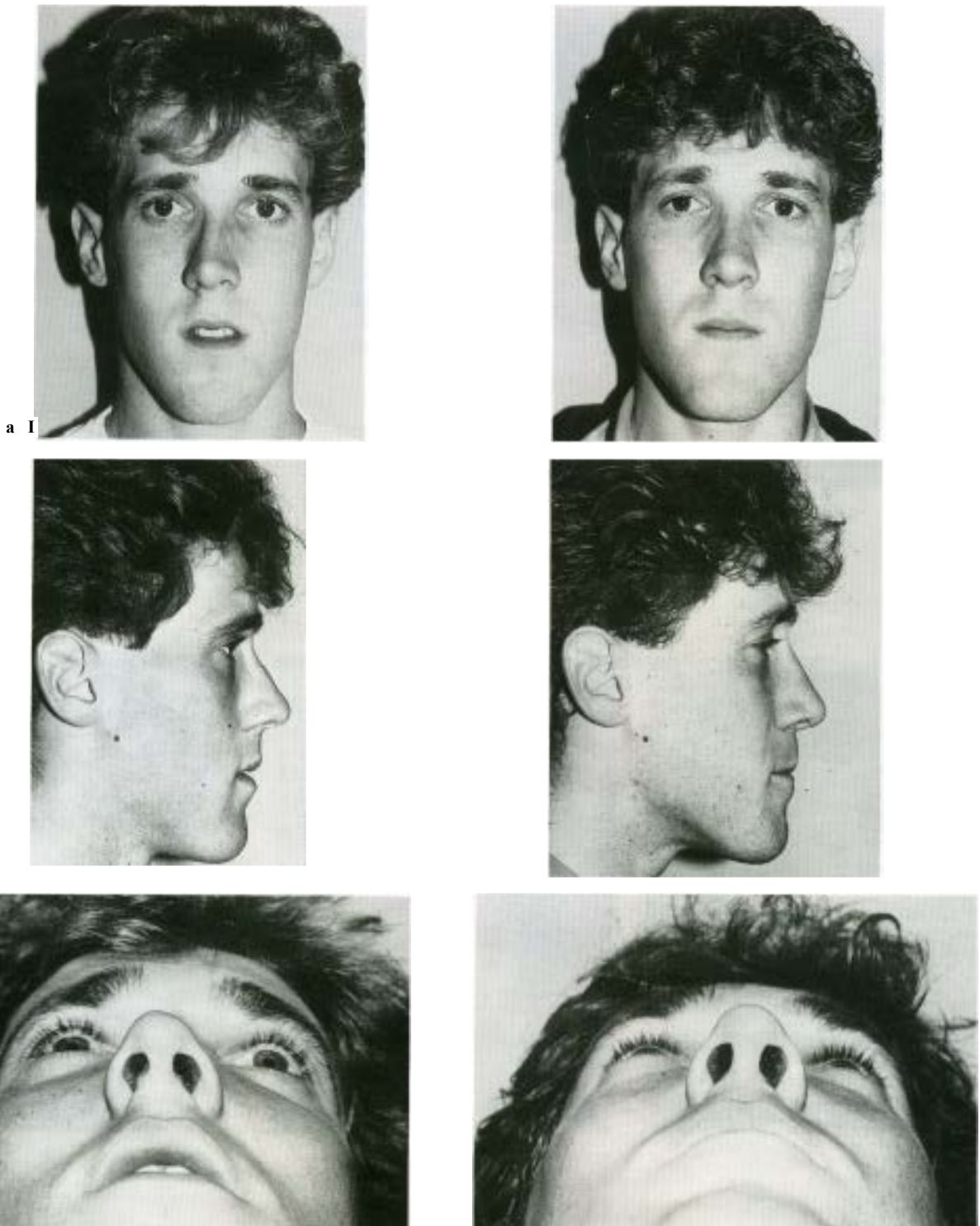
In rhinoplasty the middle nasal third is of importance for both functional and aesthetic reasons. The physiology is poorly understood while proper evaluation of the pathophysiology is difficult. Moreover, a nasal valve problem is difficult to correct, making prevention of utmost importance. Treatment of functional and aesthetic problems should aim at widening the



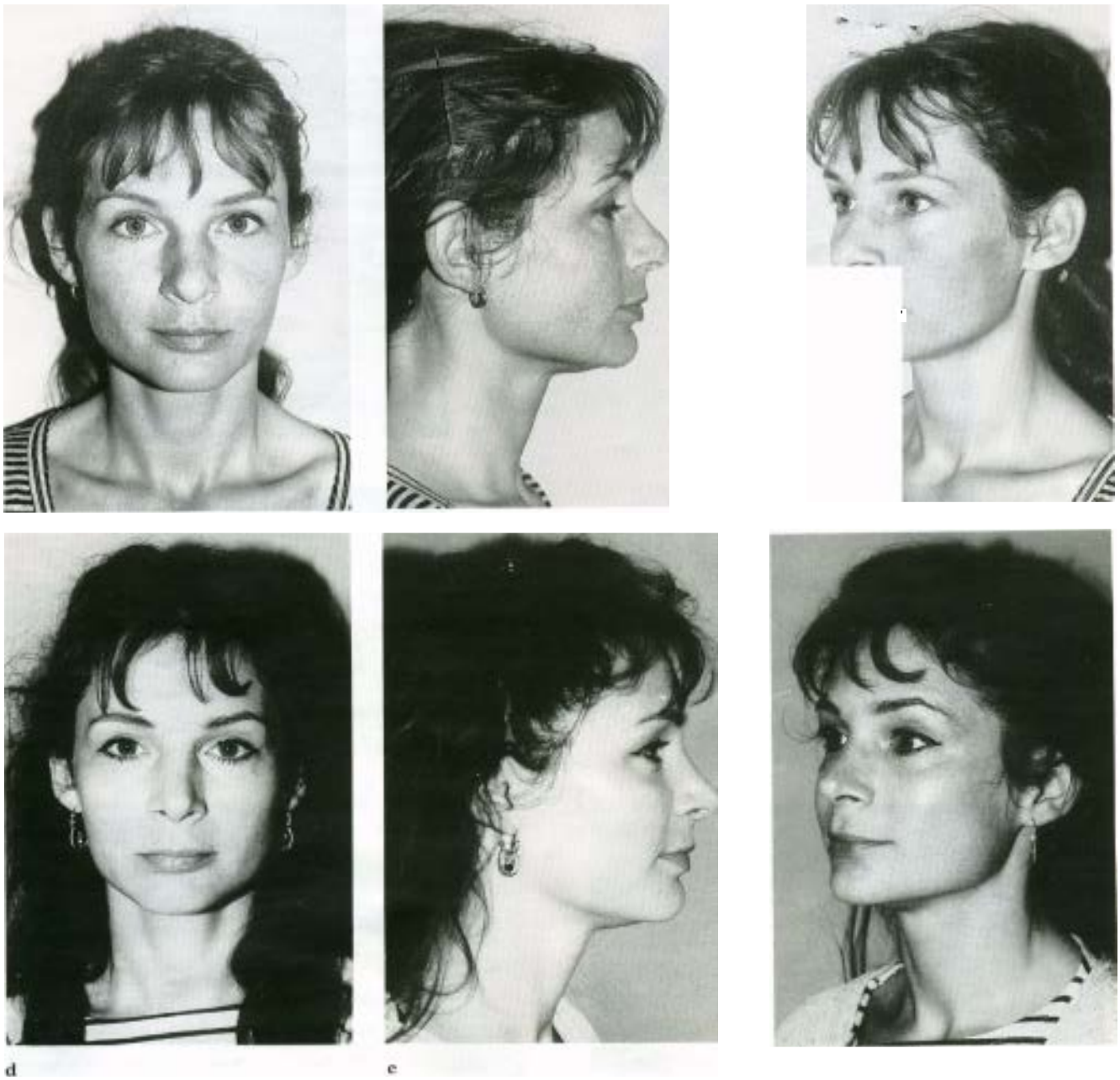**Figures 5 a, b, c, d, e, f**

Lateral and dorsal augmentation of the nose for functional and aesthetic reasons after previous rhinoplasty. Spreader grafts on both sides ; on the right side reaching up into the bony vault to support a collapsed nasal bone. Cartilage tip graft, columellar strut and cartilage dorsal only graft used for profile reconstruction.

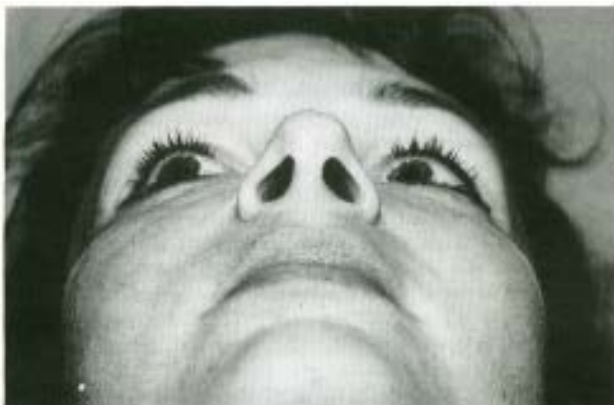
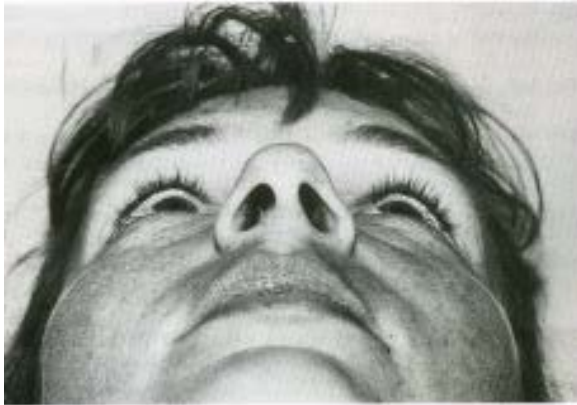


**Figures 6 a, b, c, d, e, f**  
Deviation of bony and cartilaginous pyramid with tissue loss in left middle nasal third corrected with left sided spreader graft (cosmetic indication).



**Figures 7 a, b, c, d, e, f, g, h**  
Spreader grafts used to reconstruct the middle nasal third after bony and cartilaginous hump reduction and loss of middle nasal third width (functional and cosmetic indication).



NV angle and NV area, while functional problems may also be improved by increasing support of the lateral nasal wall. Many techniques have been described, testifying to the difficulties involved.

Shortening of the upper lateral cartilage [8] should be viewed with scepticism. Although the nasal valve angle is increased, the support of the lateral wall of the nasal valve may be weakened. The applications of lower lateral cartilage rotation [21] are not clearly defined but this technique seems to be rarely indicated. Moreover, cosmetic sequelae, such as supratip fullness and alar retraction may be anticipated. Z-plasty with transposition of cephalic margins

of lower lateral cartilage [22] is difficult and may cause dorsal irregularities and alar retraction as well. Hump replacement to reconstruct the middle nasal third after reduction rhinoplasty [27] leaves the surgeon with uncertainty regarding the dorsal nasal profile. The effect of simple outfracture of the nasal bones [8] will be diminished to a large extent by scar formation.

Cartilage spreader grafting has distinct advantages over previous techniques and may be a straight forward solution for both functional and aesthetic problems concerning the middle third of the nose. Spreader grafting does not preclude the use of ancillary techniques for rhinoplasty and can be combined with other techniques to correct nasal valve problems. The open approach has increased knowledge of the surgical anatomy and understanding of pathophysiology of the middle nasal valve. Moreover, placement of cartilage grafts in the middle nasal third is greatly facilitated using the open approach.

Our functional improvement rate is highly acceptable regarding the fact that middle nasal third problems are difficult to correct. Our mean follow-up of 8 months is relatively short. However, given the long-term survival rates of autogenous cartilage grafts, we have no reason to assume that our results will decline in the future. Nevertheless, we intend to follow these patients over a longer period of time. In earlier cases with functional problems, we used a single layer of cartilage for lateral augmentation. Double grafts may have yielded greater functional success but possible unaesthetic widening is to be accounted for. Moreover, changes of cartilage resorption are increased using double cartilage grafts as the medial graft may lack adequate blood supply.

The large number of sites in which spreader grafts were used for both functional and aesthetic purposes underlines the relationship between form and function in nasal valve problems. If any comment must be made on our aesthetic result in retrospect, it can be said that we have undercorrected rather than overcorrected any pinching of the middle nasal third. We found spreader grafts especially helpful to camouflage any asymmetry if this asymmetry accentuated a nasal deviation.

We suggest that rhinoplastic surgeons should bear in mind reconstruction of the physiological T-shape of the cartilaginous middle nasal third after excessive reduction of the nasal dorsum. Especially in patients with short nasal bones and long upper lateral cartilages this may prevent aesthetic and functional sequelae.

Owing to our experience with spreader grafting in 74 patients, we intend to continue using this versatile technique for functional and aesthetic problems of the middle nasal third. The open approach will probably bring this technique within reach of many rhinoplastic surgeons.

## References

- [1] Mink PJ. Physiologie der oberen luftwegen, Leipzig, 1920, Cited by Uddstromer M. 1940. Nasal respiration. *Acta Otolaryngology*, 1920 (suppl 42).
- [2] Adamson JE. (1987) Constriction of the internal nasal valve in rhinoplasty: treatment and prevention. *Annals of Plastic Surgery*, **18**, 144-121.
- [3] De Wit G, Kapteyn TS, van Bochove WM. (1965) Some remarks on the physiology, the anatomy and the radiology of the vestibulum and the isthmus nasi. *Int. Rhinology*, **3**, 37.
- [4] Bridger GP. (1970) Physiology of the nasal valve. *Archives of Otolaryngology*, **92**, 543-553.
- [5] Haight JS, Cole P. (1983) The site and function of the nasal valve. *Laryngoscope*, **93**, 49-55.
- [6] Courtiss EH, Gargan TJ, Courtiss GB. (1984) Nasal Physiology. *Annals of Plastic Surgery*, **13**, 214-223.
- [7] Mc Caffrey TV, Kern EB. (1986) The nasal valve: a rhinomanometric evaluation of maximum nasal inspiratory flow and pressure curves. *Annales Otolaryngology Rhinology Laryngology*, **95**, 229-232.
- [8] Kern EB. (1978) Surgical approaches to abnormalities of the nasal valve. *Rhinology*, **15**, 165-189.
- [9] Goode RL. (1985) Surgery of the incompetent nasal valve. *Laryngoscope*, **95**, 546-555.
- [10] Tardy ME, DcnncnyJ, Fritsch MH. (1985) The versatile cartilage autograft in reconstruction of the nose and face. *Laryngoscope*, **95**, 523-533.
- [11] Walter CD. (1969) Composite grafts in nasal surgery. *Archives of Otolaryngology*, **90**, 106-114.
- [12] Sheen JH. (1984) Spreader graft: a method of reconstructing the roof of the middle nasal valve following rhinoplasty. *Plastic and Reconstructive Surgery*, **73**, 230-237.
- [13] Johnson CM. (1990) Open structure rhinoplasty. Philadelphia. W.B. Saunders Comp.
- [14] Wright WK, Kridel RWH. (1981) External rhinoplasty: a tool for teaching and for improved results. *Laryngoscope*, **91**, 945-951.
- [15] Adamson PA. (1987) Open rhinoplasty. *Otolaryngology. Clinics North America*, **2**, 837-852.
- [16] Masing H. (1967) Experimentelle Untersuchungen Über die Strömung im Nasenmodell. *Archives of Clinical, Ohr-Nasen-Kehlheilkunde*, **189**, 59.
- [17] May M, West JW, Hinderer KH. (1977) Nasal obstruction from facial palsy. *Archives of Otolaryngology*, **103**, 389-391.
- [18] Adamson PA, Smith O, Cole P. (1990) The effect of cosmetic rhinoplasty on nasal patency. *Laryngoscope*, **100**, 357-359.
- [19] Sheen JH. (1978) *Aesthetic rhinoplasty*. St. Louis, Mosby Comp., 310-347.
- [20] Farrior RT. (1974) Korrigierende und Rekonstruktive Plastische Chirurgie der äußeren Nase. H.H. Naumann (ed), Kopf- und Halschirurgie. Stuttgart, Georg Thieme Verlag.
- [21] Rettinger G, Masing H. (1981) Rotation of the alar cartilage in collapsed ala. *Rhinology*, **19**, 81-86.
- [22] Walter C. (1976) Zum Thema Nasenflügel Kollaps. *Laryngology Rhinology*, **55**, 447-449.
- [23] Nolst Trenite GJ. (1992) Nasal valve surgery: Z-plasty. G.J. Nolst Trenite (ed), Rhinoplasty, a practical guide to functional and aesthetic surgery of the nose. Amsterdam/New York, Kugler publications bv, **9A**, 63-67.
- [24] Vuyk HD. (1992) Open septorhinoplasty. Accepted for publication in Rhinology.
- [25] Zylker TD, Vuyk HD. (1992) Nasal valve surgery: Spreader grafts. G.J. Nolst Trenite (ed), Rhinoplasty, a practical guide to functional and aesthetic surgery of the nose. Amsterdam/New York, Kugler publication bv., **9B**, 67-75.
- [26] Adamson P, Smith O, Tropper GJ. (1990) Incision and scar analysis in open (external) rhinoplasty. *Archives of Otolaryngology Head and Neck Surgery*, **116**, 671-675.
- [27] Skoog T. (1974) Plastic surgery. New methods and refinements. Stuttgart, Georg Thieme Verlag.

Accepted July 1993