CHARTER 50

External nasal deformities

H D VUYK, P A ADAMSON

INTRODUCTION

The management of external nasal deformities involves an enormous diversity of anatomy, contours and proportions. In the face of the great variety and number of technical solutions known today, the surgeon's capability and ingenuity is taxed to tailor the management and surgery to each individual patiënt. A patiënt may present with an external nasal deformity for a number of aesthetic and/or functional reasons, sometimes also associated with elusive psyohological factors. To optimize the management process, all these need to be clarified and quantified. Only after careful pre-operative assessment of existing facial features and thoughtful planning of appropriate surgical procedures can gratifying long-term results be anticipated.

This chapter deals with the evaluation and treatment of external nasal deformities. Pertinent psychosocial aspects are reviewed and photographic documentation will be stressed. It is the knowledge of normal anatomy and aesthetics of the nose that is the key to the recognition of the various individual components of any deformity. Careful planning is stressed and surgical treatment is reviewed, focusing on the upper, middle and lower third of the nose. For management of septal deformities and skin diseases the reader is referred to the relevant chapters.

Psychosocial aspects

The patient's primary concern may be aesthetic, functional or both. Appraisal of psychosocial factors includes patiënt motivation, expectation and ego-strength (Vuyk and Zijlker, 1995). This is mandatory, especially when dealing with aesthetic concerns. An optimal doctor-patiënt relationship enhances good patiënt selection. This rapport is achieved by showing honest empathy, understanding and concern; it creates the atmosphere for patiënt management which enhances positive emotional reactions to the surgical process and its final result (Reich, 1975). The patiënt is requested to identify their specific concerns, stating the priority

of each complaint. Full disclosure of the procedure and expected results is provided, and the patiënt is given time to consider all of these issues prior to a second consultation. When both parties are satisfied that a mutually agreeable result is achievable, arrangements can be made for surgery.

Since a substantial number of poor results are based on emotional dissatisfaction rather than technical failures, it becomes essential to develop a sixth sense regarding motivation (Adamson and Kraus, 1995). Good motivation involves long-time consideration with an internal goal: to make the patiënt feel better about himself. A hurried decision for surgery made with an aim to please another person or as a part of some coping strategy should lend the surgeon to postpone or even refuse to carry out surgery.

The patiënt should be educated regarding realistic expectations. Accurate rendering of the aes-thetic goals drawn on photographs or computer generaled images are reviewed with the patiënt. Computer imaging enhances the ability of the patiënt to visualize what changes can be effected to the face, and as such, it should increase the patient's confidence in surgery. The key to prediction tracings is to be honest and ethical in what is produced on the photographs or screen. In general, it is wiser to underestimate rather than overestimate the possible surgical outcome. The surgeon must honestly point out general and specific procedural risks, including random and unpredictable events, in terms understandable to the patiënt; functional, aesthetic and psychological perspectives on the expected outcome of surgery should be provided. It should be stressed to the patiënt that the goal of facial plastic surgery is improvement, and that complete eradication of a defect or perfection is fre-quently not be achievable. The patiënt is advised that functional, aesthetic or psychological expectations might not be fully satisfied, and that a revision procedure may be necessary. Written patiënt information is used to reinforce the consultation discussions.

Photographic documentation

Pre- and post-operative photographs are a mandatory, objective form of documentation for facial plastic and reconstructive surgery. Standard poses should be taken; for the nose this includes antero-posterior, oblique (2), lateral (2) and basal views. Coexistent lesions, scars or other details may require additional standardized photographic documentation. A light-blue background works well because this colour tends to complement skin tone.

Aesthetic analysis

Comprehensive aesthetic assessment depends on a knowledge of the ideal facial characteristics, the basis of this being proportion and harmony. Gender, race, age, height and weight of the patiënt all have a bearing on the ideal facial and nasal characteristics. One wishes to see a natural look, with no one facial feature drawing unjust attention.

The face and nose are systematically analysed with the head in the Frankfort position (Figure 50.1). The frontal, profile and basal views demand specific attention. A work sheet encourages the surgeon to assess all the components of the face which may, or may not, need alteration (Figure 50.2). On anterior view, the shape of the face may vary from round, oval, oblong, heart-shaped to square. The face is rarely perfectly symmetrical, yet midline points should lie on the axis line. Vertical lines through both the medial and the lateral canthi and lateral border of helices divide the face in equal fifths. Regarding profile, the shape of the face may be convex, flat or concave. Roughly equal thirds are produced by division made at the hairline, the glabella, the subnasion and the mentum. Anterior projection of the mentum normally remains 1 to 2 mm posterior to the plane of the lower lip ver-milion border. Differences in projection of the chin are of importance as they have an impact on the visually-perceived projection of the nasal tip. Malocclusion should be noted and a determination made if the correction is required and desired.

The nose is the most prominent aesthetic unit of the face, certainly as seen on profile. The upper third of the nose is formed by the bony pyramid. The middle third of the nose corresponds anatom-ically to the upper lateral cartilages and septum. The lower third of the nose includes the nasal lobule, alae, and columella. Using this anatomie

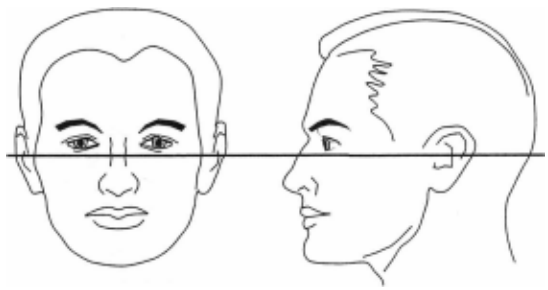

Fig 50.1 Frankfort plane transverses the top of the tragus (or auditory canal) as well as both infraorbital rims. The plane should be parallel to the floor for appropriate head position during analysis and photography.

RHINOPLASTY ASSESSMENT

PATIENT

Name: _____ Age: _____ O.R. Date: _____

Concerns: Remarks:

GENERAL

Height: _____ Weight: _____
Skin type: 1, 2, 3, 4, 5, 6
Racial background: caucasian, black, asian, middle eastern, indian, other
Skin texture: dry, normal, oily Severity:
Skin thickness: thin, normal, thick Severity:
Rhinophyma: Severity:
Acne: Severity:
Face: Round, oval, oblong, heart, square Severity:
convex, flat, concave Severity:
asymmetry Severity:
Middle third: short, equal, long Severity:
Chin: retruded, satisfactory, protruded Severity:
Occlusion: I, II, III Severity:
Scars: Other:

DORSUM

NFA Projection (Ant.): Height (Sup.):
Length Bones: Septum:
Breadth Bones: Cartilage:
Height: Hump Sloop Pollybeak Irregularity
Asymmetry: Deviated R L Convex R L Sigmoid S Reverse

BASE

Projection: Rotation:
Medial crurae Length: Width: Symmetry:
Length of upper lip: Sill: absent present
Columella Axis: straight/angled R/angled L Severity:
Projection: retracted/normal/hanging Severity:
Length: short/normal/long Severity:
Base Width: Flare:
Bifidity:
Crural angle Boxiness: Knuckling: Bifidity:
Soft angle Prominence: Symmetry:

Lateral crurae Length: Width: Width: Symmetry:
Projection: retracted/normal/hanging Severity:
Nostrils Width: Axis: Notching: Symmetry:
Alar base narrowing needed: No / ? / Yes: _____
Supratip: Fullness Severity:
Etiology: soft t./septum/ULC/ULL/skin
Tension tip:

SEPTUM

Allergy History: Tested:
Treated: Results:
Rhinitis:

Nasal obstruction: R_____ L_____ PARAMETERS:
Convex Caudal R_____ L_____
Mid R_____ L_____
Posterior R_____ L_____
Spur Anterior R_____ L_____
Posterior R_____ L_____
High deflection R_____ L_____
Inferior dislocation R_____ L_____
Turbinate size R_____ L_____
Synechia R_____ L_____
Premaxillary width:

PLAN:

REMARKS:

Fig 50.2 Rhinoplasty assessment sheet.

division, external nasal deformities can be systematically characterized (Table 50.1).

On lateral view the ideal level of the nasion is between the supratarsal fold and eyelashes of the upper eyelid (Daniel and Farkas, 1988). The height of the nasion is approximately 11 mm (range 9–14 mm) from the corneal plane as measured on a lateral view. From cephalic to caudal the height of the nasal dorsum increases in relation to the facial plane. The ideal height of the dorsum in relation to the nasal tip is different between men and women. In women the dorsum lies parallel, and approximately 2 mm posterior, to a straight line drawn from just above the nasofrontal angle to the tip defining point (Gunther and Rohrich, 1990). This difference in height can be appreciated as a supratip break. Men ideally have a higher nasal bridge with no (or only a subtle) supratip break. A natural lateral dorsal contour presents itself as a gentle convex curve instead of a straight line or scoop (Figure 50.3).

Table 50.1 Categories of external nasal deformities

Upper nasal third		
Profile	High	
	Low	
Width	wide	
	Narrow	
Symmetry		
Contour		
Irregularity and deviation		
Middle nasal third		
Profile	High	
	Low	
Width	Wide	
	Narrow	
Symmetry		
Contour		
Irregularity and deviation		
Lower nasal third		
Columella	Hanging	
	Retracted	
	Acute nasolabial angle	
Ala	Wide nasal base	
	Retraction	
Tip	Projection	Over
	Under	
	Rotation	Over
	Under	
	Amorphous	
	Pinched	
	Asymmetry	
	Contour irregularity	
	Deviation	
	Hanging infratip	
Skin	Thick	
	Thin	
	Scarring	

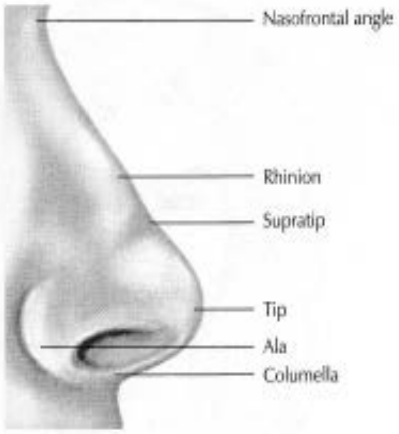

Fig 50.3 Natural lateral dorsal contour is slightly curved with the nasal tip leading profile.

The tip is the most anterior projection of the nose. Ideally the tip is well defined by the underlying domes of the lower lateral cartilages. Most aesthetically the projection of the nose has a 2/3 to 1 relationship with nasal length (Byrd and Hobar, 1993). Nasal tip projection should also be assessed relative to overall facial shape and midface length (distance from the nasion to the vermilion border of the upper lip) (Crumley and Lanser, 1988). Nasal tip rotation should be evaluated separately from nasal tip projection. The nasolabial angle is a commonly used determinator of nasal tip rotation. The angle of inclination of the long axis of the nostril on a lateral view may also be used. (Johnson and Toriumi, 1990). This latter parameter is independent of the position of the columella. On a lateral view the columella should be visible 3–4 mm caudal to the alar margin. A pseudo hanging columella may exist when alar margins are retracted (Adamson *et al.*, 1990a). The nasolabial junction should be softly curved.

On frontal view, any part of the nose should have less width than the intercanthal distance. The perceived width of the nose in the frontal view is greatly affected by the height of the nasal dorsum (a higher dorsum creates a narrower appearing nose). The dorsum should be of sufficient height to create a distinct anatomic separation of the eyes and add a third dimension to the midface area on frontal view (Sheen, 1978). The nasal dorsum can

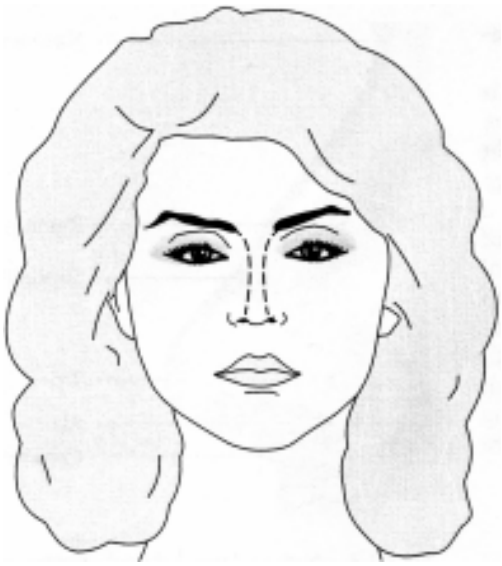

Fig 50.4 The transition of nasal dorsal plane and plane of lateral nasal wall is ideally perceived as a flowing line from the brow to the tip defining points.

be outlined by two slightly curved, flowing lines extending from the supraorbital curves to the tip defining points (Figure 50.4). These lines demarcating the nasal dorsum are actually subtle changes in light reflection upon the transition between the nasal dorsal plane and the plane of the lateral nasal wall (Constantion, 1984). The width of the nasal dorsum conforms to the interdomal width which is proportional to the width of the upper lip philtrum. From the nasofrontal angle the width increases consistent with nasal bone position and shape to a maximum at rhinion. It then decreases slightly as the upper lateral cartilages come to lie more closely to the septum, giving an overall diamond shape. Because of its position in the midline on frontal view, nasal deviation and asymmetries are readily apparent. A deviation implies the axis of the dorsum is deflected from the vertical midline. Asymmetries, on the other hand, may be caused by relative tissue deficiencies and/or differences in rel-ative position of the various components of the nose. A septal deformity can frequently be the underlying cause of deviation and/or asymmetry. In basal view the lateral walls and the base of the nose ideally form an equilateral triangle with a col-umella:lobule ratio of 2:1.

In addition to visual assessment, the nasal lobule must be palpated to assess the strength of the lower lateral cartilages and their ligamentous and cartilaginous supporting mechanisms. The dorsum is palpated to determine irregularities such as fractures, open-roof deformities, and cartilage disarticulations and weakness. Finally, consideration is given to the texture and thickness of the skin-soft tissue envelope by close inspection, palpation and rolling of the nasal skin covering. Very thick skin and very thin skin may both limit the possible final outcome of surgery. In thick skin re-drapage is limited. In thin skinned patients any small irregularity is more likely to show through.

Surgical treatment

Rhinoplasty can be performed under general anaesthesia or local anaesthesia with intravenous sedation. Local agents (Lidocaine 1%/1:100.000 and Marcaine 0.5%/1:200.000) are used to infiltrate the correct dissection planes. Subsequent surgical dissection in proper non-vascular areolar tissue planes prevents violation of muscle and thinning of skin flaps. This also diminishes bleeding, decreases post-operative oedema and reduces scar-tissue formation.

Exposure

The approach for septorhinoplasty can be either endonasal or external (open). The endonasal approach has been taught and used most commonly in the past, but the external or open approach continues to receive increased attention. The endonasal approach is established by intercartilaginous, trans-

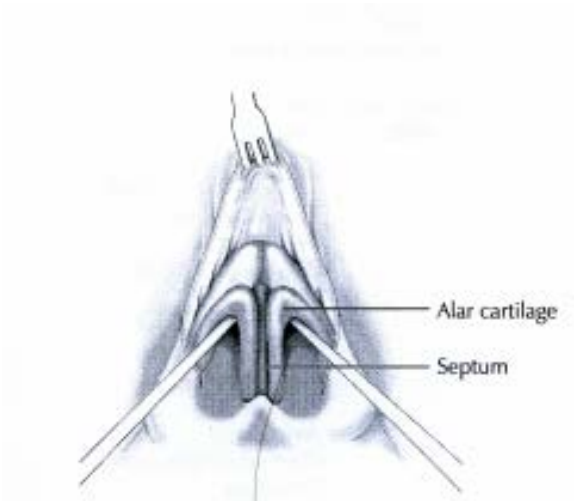

Fig 50.5 Open approach exposure of alar cartilages and nasal dorsum. Exposure may be further extended to nasal septum, premaxillary spine and nasal frontal angle.

cartilaginous or marginal incisions. In the past two decades the open approach has gained wide popularity (Anderson *et al,* 1982; Adamson, 1987, 1988; Johnson and Toriumi, 1990; Vuyk and Olde Kalter, 1993). It is in essence a 5 mm long broken transcolumellar incision, connected with two (endonasal) marginal incisions, offering an unparalleled undistorted exposure of the nasal anatomy (Figure 50.5). With proper technique, decreased columellar skin flap viability is very rare (Vuyk and Olde Kalter, 1993). The scar, which is invisible in the vast majority of patients, (Adamson *et al.,* 1990b) is a relatively small concession to the increased exposure. Whether the external approach is associated with increased supratip swelling is still debated. The choice of approach will depend on the surgeon's own preference. There are, however, no reasonable objections which can be raised against the columellar incision to reject the open approach.

Septoplasty

Although not a specific topic of this chapter, it must be stressed that the internal anatomy, specifically the nasal septum, can be intimately linked to an external nasal deformity.

Septoplasty is usually performed first to correct functional problems and obtain any cartilage that may be necessary for grafting. The septum may be approached by a Killian incision for posterior deformities or a hemitransfixion incision if anterior septal work is needed. The external approach with separation of medial crura from each other and the upper lateral cartilages from the septum may be helpful in cases of more severe septal deformities. The open rhinoplasty approach offers superb, undis-torted exposure of the septum from the rhinion to the nasal spine. This exposure facilitates septal cartilage weakening by scoring and castellation, realignment by spinal suturing and reconstruction with cartilage battens and grafts. However, the view is more anterosuperior than seen in closed tech-niques and may require some orientation adjust-ment in the mind's eye. For septal perforation closure requiring fascia and cartilage grafting in combination with mucoperichondrial, mucope-riosteal flaps, the open approach is preferred and used almost exclusively (Vuyk and Zijlker, 1992).

Upper nasal third

Generally, the upper third of the nose is treated bef ore proceeding to the middle and lower third of the nose. Bony contouring is more traumatic compared to the delicate tip reconstruction. Moreover, the height of the dorsum may be set at a predetermined level to which the nasal tip position can be matched. The position of the bony vault relative to the midline may also influence the position of the middle third and nasal tip. Therefore, realignment of bony vault must precede final refinement of middle third and nasal tip in cases of deviations and asymmetry. The soft tissues and periosteum over the nasal bones are raised as far as necessary to enhance subsequent camouflage and cushioning, without compromising periosteal support to the nasal bones.

The nasofrontal angle can be deepened conservatively using a rasp, an osteotome or a burr. One should bear in mind that the soft tissue response to reduction of the nasofrontal angle is often less than anticipated. More predictable is augmentation of the nasofrontal angle using lightly crushed autoge-nous cartilage grafts. Nasal frontal angle augmentation is performed after contouring and alignment of the bony vault.

Either an osteotome or a rasp can be used to reduce the bony nasal dorsum. Generally the osteotome is reserved for larger reductions and a rasp for smaller reductions and refinements. Medial osteotomies are performed in the case of bony vault deviations, asymmetries or in the case of a broad

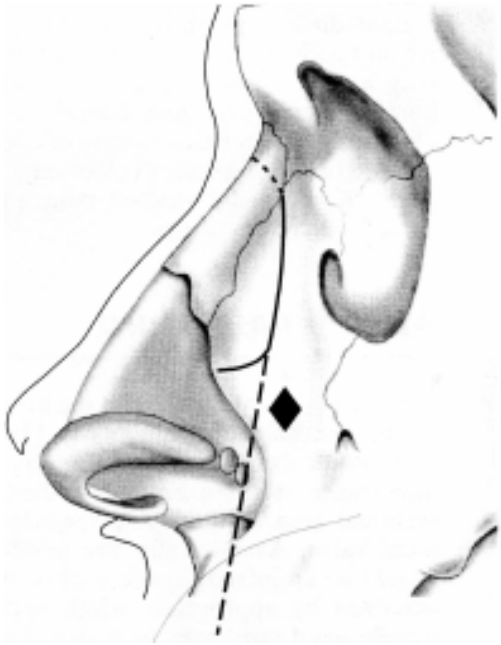

Fig 50.6 Lateral osteotomy line with preservation of a bony triangle and the piriform aperture (*) and backfrac-ture at medial canthus.

nose without a hump. Low lateral osteotomies to close an open dorsum or to narrow or straighten the nasal pyramid are carried out through separate incisions over the margin of the piriform aperture, with or without elevation of the periosteum. The lateral osteotomy is started at the pyriform aperture at or just above the inferior turbinate (Figure 50.6). A small triangle of bone is preserved to prevent collapse of the inferior pyriform aperture which could cause airway problems. Subsequently the low osteotomy line curves up along the nasomaxillary junction to the level of the medial canthi. Gentle inward movement of the osteotome usually produces a back fracture and the nasal bones can be repositioned.

Outfractures are usually omitted unless the bones require further mobilization. If adequate infracture is still not possible, external transcutaneous, transverse osteotomies using a 2 mm osteotome may be performed. Although the nasal bones can be fractured and repositioned in a relatively controlled fashion, caution is advised in patients with short or brittle nasal bones or in those with a low nasal bridge, because an increased risk of collapse or 'eggshelling' of the bones exists. Should this occur, the nasal bones may be supported with methylcellulose (Surgicel) packing. The relative positions of the nasal bones and upper lateral cartilages with respect to the septum may be altered with osteotomies. Therefore, final refinement of the dorsum is performed after the osteotomies are completed.

Immediate pressure is applied to prevent bleeding and ecchymosis. In extremely broad noses with only a small hump, infracture is facilitated after burring away bone just lateral to the midline. Doublé osteotomies, consisting of a low and a high lateral (or intermediate) osteotomy, may be indicated in a broadly vaulted bony pyramid or to correct severe deviations.

Middle nasal third

Surgery of the middle third of the nose remains one of the challenges in rhinoplasty (Toriumi, 1995). The middle nasal third is of the utmost functional importance, as its corresponds to the smallest cross-sectional area of the whole respiratory tract, the nasal valve. Aesthetically, the middle nasal third should be an inconspicuous part of the nose characterized by appropriate width and height. The middle nasal third may be widened effectively for both functional and aesthetic purposes by placement of autogenous cartilage grafts between the dorsal aspects of the nasal septum and upper lateral

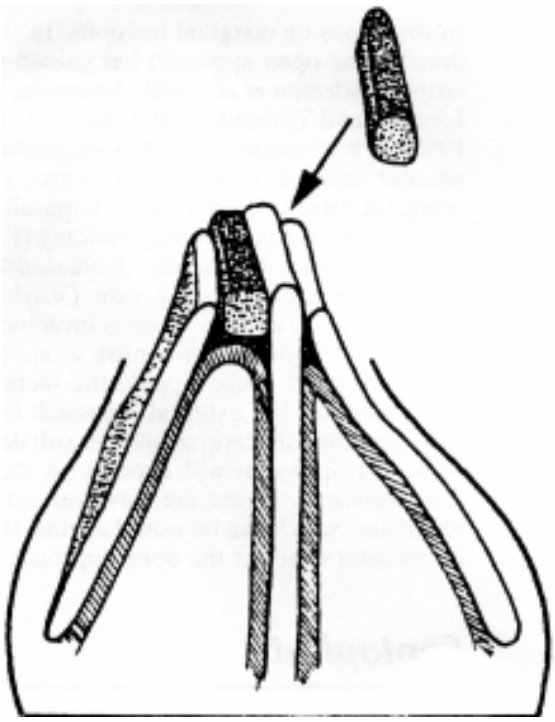

Fig 50.7 Cartilage batten (spreader graft) placed between upper lateral cartilages and septum.

cartilages (Vuyk, 1993) (Figure 50.7). These grafts consist of a flat rectangular piece of cartilage averaging 20-25 mm in length, 3-5 mm in width, and 2-3 mm in thickness. More subtle widening can be obtained by using the cephalic portion of the lower lateral cartilages. Spreader grafts can even be extended between the nasal bones if indicated. With this type of nasal valve surgery an 85% functional improvement rate may be obtained (Vuyk, 1993). A unilateral middle third dorsal concavity caused by a septal curve or upper lateral cartilage deformity can be improved aesthetically by placement of a spreader graft along the concave side, with concomitant improvement in function. These grafts can be secured by horizontal mattress sutures which still allow subsequent dorsal refinement.

Alternatively, onlay grafts can be used to fill the concavity thereby 'straightening' the upper lateral cartilages. They can be secured transcutaneously with 4.0 plain gut sutures for 4 days.

Augmentation of the nasal dorsum remains an area of challenge and controversy. Nasal dorsal augmentation may be defined as the addition of autogenous or alloplastic materials to alter the contour and achieve a more natural form. Most often only part of the cartilaginous and bony nasal dorsum is in need of augmentation. In selected cases the whole

nasal dorsum requires augmentation, taxing the surgeons ingenuity with regard to the technique of repair and the choice of implant material. Autogenous cartilage grafts are the most frequently used materials for augmentation (Adams, 1987). Infection and resorption of autogenous cartilage grafts in the nose are extremely rare. Autogenous cartilage is easily manipulated, while its inherent resilience lends support to the reconstruction. Septal cartilage is preferred with auricular cartilage as the second choice. At times, however, adequate aut cartilage is not readily available and suıtı-cıent quantities of a suitable substitute are needed. Indeed, the relatively large volume of material nec-essary for total nasal dorsal augmentation has enticed surgeons to use other biomaterials such as autogenous bone (Cheney, 1993), homografts (Kridel and Konior, 1993) and various alloplasts (Stucker, 1977; Beekhuis, 1980; Rothstein and Jacobs, 1989; Flowers, 1994).

Regarding the mechanical properties and tissue ingrowth characteristics, expanded polytetrafluoroethylene (Goretex™) may perhaps be the optimal synthetic material when extensive nasal dorsal augmentation is indicated (Vuyk, 1997).

Lower nasal third

The statement of Fomon; 'He who masters the tip masters rhinoplasty,' underscores the importance of control over nasal tip shape, projection and rota-tion. During rhinoplasty the surgeon strives to preserve or change these major nasal tip characteristics in a predictable and permanent fashion (Adamson, 1993). Conservation, relocation and augmentation of tissues have replaced reduction and resection as the modern principles of rhinoplasty surgery. Table 50.2 lists various nasal tip surgery techniques listed according to their predominantly conservative or aggressive nature.

To decrease fullness in the lateral supratip region, a conservative volume reduction of the cephalic portion of the lower lateral cartilages is usually sufficient. To prevent distortion of the ala by scar tissue retraction a complete strip of at least 8-9 mm in width should be maintained. Further contour and position changes of the nasal tip can be induced predictably in a graduated fashion by re-orienting the medial, intermediate and lateral portions of the alar cartilages, and maintaining position using (semi-)permanent sutures (PDS) (Vuyk, 1995; Tebbets, 1994). Three complementary techniques can be distinguished: interdomal sutures (Joseph, 1931); transdomal sutures (McCollough and English, 1985; Tardy and Cheng, 1987); and

Table 50.2 Techniques for nasal tip surgery. A list of nasal tip surgery techniques with subdivision according to nature of surgery

Conservative	Aggressive
Complete strip	Rim strip§
Permanent suture	Lateral crural flap¶
Cartilage overlay*	Vertical dome division[1]
Scoring†	Morsilization**
Cartilage grafting‡	

* Cartilage overlay involves a vertical division of the middle or lateral crurae, with subsequent overlay of both ends and suture reconstitution

† It should be noted that deep and wide scoring may weaken the cartilage to the same degree as morsilization.

‡ Autogenous cartilage tip grafting is conservative in the sense that it adds strength to the nasal tip, however, the changes in contour aimed for, must be controlled conspicuously.

§ Rim strip involves resection of the lateral most portion of the alar cartilage

¶ Lateral crural flap involves resection of a medial part of the lateral crurae with preservation of the lateral part of the lateral crurae.

[1] Vertical dome division involves vertical transection anywhere in the domal region with or without cartilage resection and suture reconstitution.

** With morsilization cartilage is weakened while the volume of cartilage increases; both changes diminish control over this surgical manoeuvre.

lateral crural steal (Kridel *et al,* 1989) [Figure 50.8(a)-(c)]. The interdomal suture aims to decrease the interdomal distance and strengthen the medial crural complex.

Transdomal suturing techniques involve a horizontal mattress suture incorporating both intermediate and lateral crurae, and are used to reposition the intermediate alar cartilage segment and lateral crurae in a more acute angle. Transdomal suturing transforms a flat, non-distinct domal region into a more natural, smooth convex segment, thereby creating an aesthetically pleasing, well-defined dome.

The lateral crural steal involves horizontal mattress sutures placed just medial to or at the dome and extending laterally into the lateral crurae. This manoeuvre lengthens the intermediate crurae at the expense of the lateral crurae, enhancing tip projection and rotation (Kridel *et al,* 1979). Increased medialization of the lateral crus can be obtained by a vertical incision through the hinge area to release the lateral crus.

Vertical division of the medial or lower lateral crurae with overlap and suture fixation of cartilage is a powerful tooi to alter projection and rotation

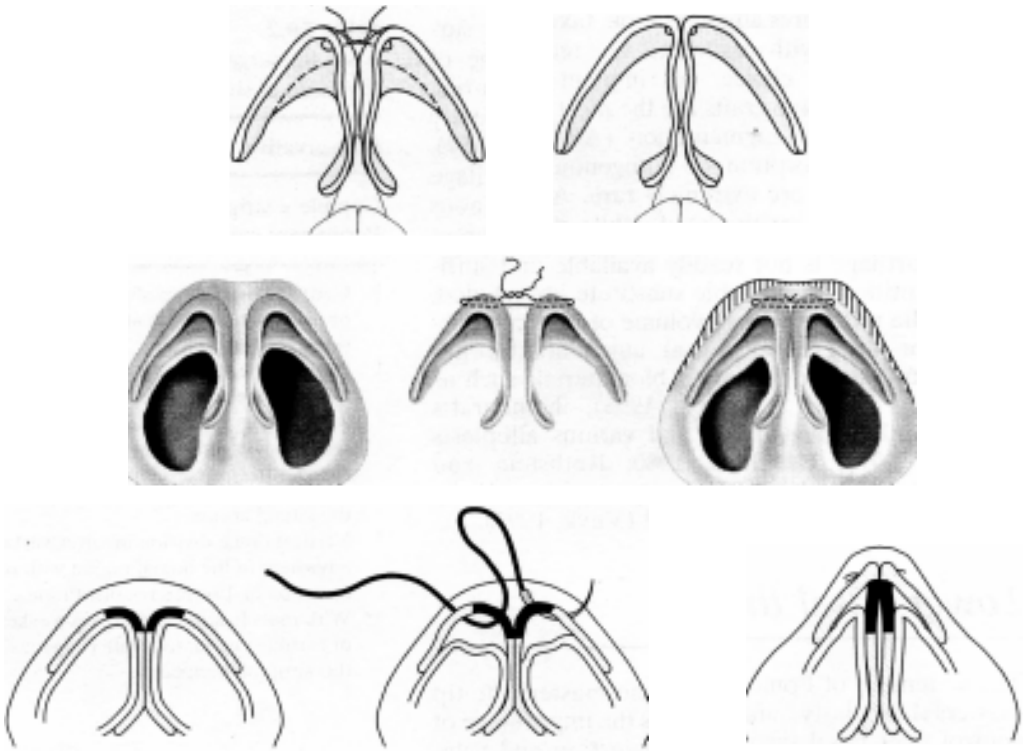

Fig 50.8 Three types of alar cartilage reshaping sutures: (a) interdomal sutures; (b) transdomal sutures; (c) lateral crural steal.

and correct lobular deformities (McGraw and Adamson, 1994; Adamson and Morrow, 1994; Kridel and Konior, 1991).

A columellar strut is a piece of cartilage inserted between the intermediate and medial crurae and is used in almost every patiënt (Figure 50.9). This type of cartilage graft lends strength to the intermediate and medial crurae and increases tip support (Vuyk *et al.,* 1997). The graft extends from just above the nasal spine to the upper level of the nostrils just below the domes of the alar cartilages, and is secured with transfixion sutures. By changing the angle of its placement in the inferior columella, the strut can also be used to augment the nasolabial angle or increase columellar prominence. Batten type onlay grafts to the medial crurae are used to augment the columella or camouflage columellar asymmetries. In the case of a hanging columella, the caudal margin of the medial crura may be trimmed, the septum shortened, and a bulky membranous septum excised, depending on the anatomie deformity.

Autogenous cartilage onlay grafts to the nasal tip add structure to the lower lateral cartilages and support to the nasal skin soft tissues, inducing predictable changes on a long term basis (Johnson and Toriumi, 1990; Zijlker and Vuyk, 1993; Sheen, 1993). Depending on the location, size and shape of these grafts, nasal projection, rotation and contour are controlled (Figure 50.10). These grafts are

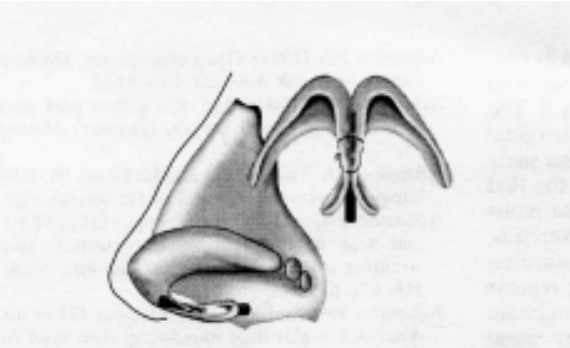

Fig 50.9 Columellar strut placed in between medial crurae.

usually secured with 6.0 semi-permanent sutures to the alar cartilages. Final refinement of the graft is deferred until it has been secured to obtain ideal position and shape. Measurements on photographs have shown that cartilage grafts are one of the most predictable manoeuvres to increase nasal tip projection (Vuyk *et al.,* 1997). Similarly, the lower lateral cartilages may be grafted to increase structural support in cases of previous over-resection or for correction of alar concavities and alar rim retraction.

Premaxillary nasolabial augmentation may be indicated after iatrogenic shortening of the inferior aspect of the caudal septum or after excision of the premaxillary spine. A precise premaxillary subperiosteal pocket is made to accommodate the implant material. Autogenous cartilage or tempo-ralis fascia are satisfactory, but the volume avail-able is often not sufficient to produce significant change. Alloplastic biomaterials such as expanded polytetrafluoroethylene (Goretex™) soft tissue sheeting may be preferred. The premaxilla probably tolerates a maximum of 4 mm augmentation. A greater volume increases the risk of an unnatural feel and extrusion. Premaxillary deepening is easily performed by excising premaxillary soft tissue and bone.

Final refinements

The upper lateral cartilages are secured to the nasal septum with horizontal mattress sutures. Small cartilage irregularities are trimmed, and bony deformities are rasped. Small cartilage and soft tissue grafts are placed to fill any areas of depression, such as caused by a bone chip or open roof deformity. Previously resected portions of the lower lateral cartilages have proved versatile because of their soft consistency. Fibrin glue is extremely helpful in

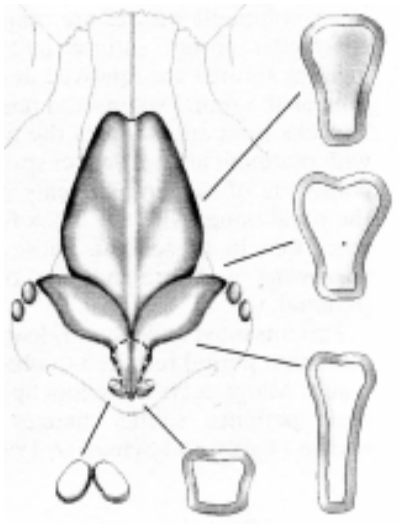

Fig 50.10 Tip grafts in various shapes, degrees of thick-ness and positions can be used to effect changes in tip projection, rotation and to camouflage asymmetries. Moreover, a tip graft can increase nasal length, augment the columella and produce a more defined nasal lobule.

the fixation of these small grafts until the cast is applied. Alternatively, transcutaneous sutures may be used for this purpose.

Alar narrowing is considered if the alae extend lateral to the perpendicular line dropped from the medial canthus. Alar refinement is particularly common when large noses are reduced and the nasal tip deprojection causes flaring of the alae. Appropriate geometrie excision in the skin is carried out, sometimes combined with a back-cut placed just above the alar facial groove (Adamson *et al,* 1990e). This technique narrows the nasal base, decreases nostril size, and alters the nostril axis.

All incisions are sutured, the nose is taped and splinted, and the procedure thus completed. The operation report is dictated and graphically recorded. These graphic charts are combined with long-term follow up to facilitate instructive self-analysis.

Post-operative care

Patiënt compliance in the post-operative period is enhanced by using written instructions.

Appropriate arrangements for emergency care should always be available. Nasal packing, which consists of a small piece of methylcellulose

(Surgicel) or 'Telfa' pad, is removed as soon as possible, usually on day l or 2. If the approach has been open, columella sutures are removed at day 5. The columellar corner sutures and vertical marginal incision sutures are removed at day 7, at the same time as the septal splints and nasal cast. In the first 2 weeks the patiënt keeps the nasal mucosa moist with ointment and salt-water spray. Nasal exercises, consisting of moderate, evenly placed pressure on the nasal bones with the index fingers on a regular basis, may be prescribed. These exercises maintain narrowing and straightening of the bony nasal pyramid.

Patients must understand clearly that l year is the minimum period required to observe the near-final result. Many years of follow-up do show that in a most patients, subtle changes will continue to evolve (Tardy and Schwartz, 1993).

Complications

Complications are an inescapable potential consequence of any surgical procedure. As rhinoplasty falls under the designation of elective surgery, post-operative Complications are particularly distressing to both physician and patiënt (Holt *et ai,* 1987). Most aesthetic and functional Complications of rhinoplasty are related to improper patiënt selection, inadequate patiënt evaluation and faulty surgical technique.

Complications such as post-rhinoplasty infections and haemorrhage are infrequent (2-4%) (Goldwyn, 1979; Lawson *et al.,* 1983). Local cellulitis or abscess of nasal skin, vestibule, columella or septum generally respond well to antibiotics and/or drainage. More severe infections can occur, but are extremely rare. Haemorrhage may be due to a coagulopathy which may be hereditary or, more often, drug induced and usually repacking is all that is required. Other rare Complications, include the toxic shock syndrome (Teichgraber and Russo, 1993).

The most desirable way to manage Complications is to prevent them. Such successful management includes proper pre-operative preparation and counselling and close post-operative supervision with appropriate care.

References

Adams JS (1987) Grafts and implants in nasal and chin augmentation: a rational approach to material selection. *Otolaryngology Clinics of North America* 20: 913-930.

Adamson PA (1987) Open rhinoplasty. *Otolaryngology Clinics of North America* 20(4): 837. Adamson PA (1988) Open rhinoplasty: past, present and future. *Facial Plastic Surgery Quarterly Monographs* 5: (2). Adamson PA, Tropper GJ and McGraw, BL (1990a) The hanging columella. *Journal of Otolaryngology* 19: 5.

Adamson PA, Smith O and Tropper GJ (1990b) Incision and scar analysed in open (external) rhinoplasty. *Archives of Otolaryngology, Head and N eek Surgery* 116: 671-675. Adamson PA, Smith O and Tropper GJ *et al* (1990e) Analyses of alar base narrowing. *American Journal of Cosmetic Surgergy* 7(4): 239-243.

Adamson PA (1993) Nasal tip surgery in open rhinoplasty. *Facial Plastic Surgery Clinics of North America* 1(1): 39-52. Adamson PA and Morrow TA (1994) The nasal hinge. *Otolaryngology, Head and N eek Surgery* 14: 219-231.

Adamson PA and Kraus WM (1995) Management of patiënt dissatisfaction with cosmetic surgery. *Facial Plastic Surgergy Quarterly Monograph 2:* 99-104.

Anderson JR, Johnson CM and Adamson PA (1982) Open rhinoplasty: an assessment. *Otolaryngology, Head and Neck Surgery* 90: 272. Beekhuis GJ (1980) Polyamide mesh used in facial plastic surgery. *Archives of Otolaryngology, Head and Neck Surgery* 106: 642-644. Byrd HS and Hobar PC (1993) Rhinoplasty: a practical guide for surgical planning. *Plastic and Reconstructive Surgery* 91(4): 642-645. Cheney ML (1993) Reconstructive grafting by the open nasal approach. *Facial Plastic Surgery Clinics of North America l* (1): 99-109.

Constantion MB (1984) Toward refinement in rhinoplasty. *Plastic and Reconstructive Surgery* 74(1): 19-31. Crumley RL and Lanser M (1988) Quantative analyses of nasal tip projection. *Laryngoscope* 98: 202-208. Daniel RK and Farkas LG (1988) Rhinoplasty: image and reality. *Clinics in Plastic Surgery* 15: 1. Flowers RS (1994) Nasal augmentation. *Facial Plastic Surgery Clinics of North America 2:* 339-356. Goldwyn RM (1979) Unexpected bleeding after elective nasal surgery. *Annals of Plastic Surgergy* 3: 201-204.

Gunther JP and Rohrich RJ (1990) Augmentation rhinoplasty: dorsal onlay grafting using shaped autogenous septal cartilage. *Plastic Reconstructive Surgery* 86(1): 39-45.

Holt GR, Garner ET and McLarey D (1987) Post-operative sequelae and Complications of rhinoplasty. *Otolaryngology Clinics of North America* 20: 853-856. Johnson CM and Toriumi DM (1990) *Open Structure Rhinoplasty* Philadelphia: WB Saunders. Joseph J (1931) Nasenplastik und sonnstigen Gesichts-plastik nebst mammoplastik. Leipzich. C. Kabitsch.

Kridel RWH, Konior RJ, Shumrick KA and Wright WK (1989) Advances in nasal tip surgery, the lateral crural steal. *Archives of Otolaryngology, Head and Neck Surgery* 115: 1206-1212. Kridel RWH and Konior RJ (1991) Controled nasal tip rotation via the lateral crural overlay technique.

Archives of Otolaryngology, Head and N eek Surgery 117:411-415. Kridel RW and Konior RJ (1993) Irradiated cartilage grafts in the nose; a preliminary report. *Archives of Otolaryngology, Head and Neck Surgery* 119: 24-30. Lawson W, Kessler S and Biller HF (1993) Unusual and fatal complications of rhinoplasty. *Archives of Otolaryngology* 109: 164-169. McCollough EG and English JM (1985) A new twist in nasal tip surgery. An alternative to the Goldman tip for the wide or bulbous lobule. *Archives of Otolaryngology* **111:** 524-529. McGraw BL and Adamson PA (1994) Vertical dome division in open rhinoplasty: an update on indications, techniques, results. *Archives of Otolaryngology* 120: 373-380. Reich J (1975) Factors influencing patients satisfaction with results esthetic plastic surgery. *Plastic and Reconstructive Surgery* 55: 5-13. Rothstein SG and Jacobs JB (1989) The use of Goretex implants in nasal augmentation operations. *ENT Journal* 41-45. Sheen JH (1978) *Aesthetic Rhinoplasty* 2nd edn. St Louis: Mosby. Sheen JH (1993) Tip graft: a 20-year retrospective. *Reconstructive Surgery* 91: 48-63. Stucker FJ (1977) Use of implantation in facial deformity. *Laryngoscope* 87: 1523-1527. Tardy ME and Cheng E (1987) Transdomal suture refinement of the nasal tip. *Facial Plastic Surgery* 4: 317-326. Tardy ME and Schwartz MS (1993) The evolution of the rhinoplasty outcome: long-term results, Chapt 32. In: *Aesthetic Plastic Surgery: Rhinoplasty* (ed. K Daniel). Boston: Little Brown. Tebbetts JB (1994) Shaping and positioning of the nasal tip without structural disruption: a new, systematic approach. *Plastic Reconstructive Surgery* **94:** 61-77. Teichgraber JS and Russo RC (1993) Treatment of nasal surgery complications. *Annals of Plastic Surgery* **30:** 80-88. Toriumi EN (1995) Management of the middle nasal vault in rhinoplasty. *Operative Techniques in Plastic Reconstructive Surgery 2:* 16-30. Vuyk HD and Zijlker TD (1992) Nasal septal perforations, Vol. 4, Chap. 31. In: *Otolaryngology,* ed. English. New York: Lippincott. Vuyk HD and Olde Kalter P (1993) Open septorhinoplasty, experiences in 200 patients. *Rhinology* 31(4): 175-182. Vuyk HD (1993) Cartilage spreader grafting for lateral augmentation of the middle third of the nose. *Face* 3: 159-170. Vuyk HD and Zijlker TD (1995) Psychosocial aspects of patients counselling and selection: a surgeon's perspective. *International Quarterly Monographs* 11: pp 55-60. Vuyk HD (1995) Suture tip plasty. *Rhinology* 33: 30-38. Vuyk HD (1997) Total nasal dorsal augmentation: autogenous or synthetic biomaterial? In press. Vuyk HD, Oakenfull C and Plaat RE (1997) Nasal tip projection changes after open rhinoplasty: an objective appraisal. *Rhinology,* in press. Zijlker TD and Vuyk HD (1993) Cartilage graft for the nasal lobule. *Clinical Otolaryngology* 18(6): 446^458.