

## Main Articles

# Treatment of chondrodermatitis nodularis with removal of the underlying cartilage alone: retrospective analysis of experience in 37 lesions

J. A. DE Ru, M.D., P. J. F. M. LOHUIS, M.D., Ph.D.\*<sup>†</sup>, H. A. SALEH, F.R.C.S. (ORL-HNS)\*,  
H. D. VUYK, M.D., Ph.D.<sup>†</sup>

### Abstract

Most otolaryngologists treat patients with chondrodermatitis nodularis (CDN) by wedge excision. Although the results of this technique are generally good, it can leave the patient with an asymmetric, deformed ear.

In the dermatological literature, a relatively straightforward technique has been described for the treatment of CDN by smoothing only the underlying cartilage. This is based on the assumption that CDN is caused by pressure necrosis of protuberant cartilage, and thus is primarily not a skin disease. Reports on this technique claim excellent cosmetic results with only a small chance of recurrence.

In the present study we analyse the application of this technique to 34 patients with 37 CDN lesions. All patients were symptom-free with a minimum follow-up of three months according to their medical reports. Seventeen patients with 19 lesions were interviewed later by telephone. In a mean follow-up of 30.7 months, 34 of these patients remained symptom-free and only one required revision surgery. The authors recommend this safe and simple technique to other physicians who treat patients with CDN.

**Key words:** Ear, External; Chondrodermatitis; Surgical Procedures, Operative

### Introduction

Chondrodermatitis nodularis (CDN) is a reddish grey, inflammatory nodule of the external ear. The lesions are sometimes covered with a scale or crust, and exquisitely tender. Although CDN usually involves the outer rim of the helix, it can also affect the anthelix.<sup>1</sup> The lesions seem to be persistent in most cases, but do not become malignant.<sup>1</sup> The characteristic location, appearance and pain usually support the diagnosis and histological examination is only performed to exclude cancer. Histologically CDN exhibits dermal inflammation and fibrosis with either a central hyperkeratotic plug or ulceration. The underlying cartilage is usually disrupted, haemorrhagic and sometimes even necrotic.<sup>1</sup>

Controversy prevails as to the aetiology of CDN. In the past, cold, trauma and sun damage have been suggested. However, more recently, degenerative change of cartilage and overlying skin as a result of pressure necrosis is thought to be the most important factor.<sup>1-4</sup> This is consistent with the observation that

CDN usually develops on the preferred sleeping side. Furthermore, the skin of the pinna is tightly stretched over the underlying cartilage and the circulation in the area is poor because there is little subcutaneous tissue between the cartilage and the skin.<sup>5</sup> Most often the lesions develop on the most protuberant part of the ear, i.e. in males more often on the helix, and in females on the anthelix. Contralateral lesions appear if patients alter their sleeping posture because the first ear is too painful to sleep on.<sup>3</sup> Symptoms may simply start because the cartilage becomes less flexible with increasing age and is hence more vulnerable to pressure damage,<sup>3</sup> as older people tend to move less during sleep.

A wide variety of surgical and conservative treatment options have been proposed. They include topical antibiotics and/or corticosteroids, curettage,<sup>6</sup> cryotherapy, vaporization with carbon dioxide laser,<sup>7</sup> shave excision and wedge excision. Although corticosteroid injection is sometimes successful (10-20 per cent) as an initial treatment, the large majority of

From the Department of Otolaryngology/Head and Neck Surgery, UMC Utrecht, European Academy of Facial Plastic and Reconstructive Surgery\*, and the Department of Otolaryngology/Facial Plastic and Reconstructive Surgery†, Gooi Noord Ziekenhuis, Blaricum, The Netherlands.

Accepted for publication: 30 April 2002.

patients eventually require further treatment.<sup>2,8</sup> Good results have been described with wedge excision with recurrence in up to 10 per cent of the patients, mostly at the margins of the excised cartilage.<sup>1,3</sup> However, wedge excision (especially after one or more recurrences) can leave a patient with an asymmetrical or deformed ear.<sup>1,3</sup> Simple elliptical excision resulted in an 18 per cent recurrence, although it was more effective in combination with adjuvant curettage.<sup>6</sup> Using a CO<sub>2</sub> laser, Taylor (1991) reported excellent healing with no recurrence in 12 cases with a follow-up of two to 15 months.<sup>7</sup> These data seem promising, although long-term results are still awaited.

Ceilley and Lillis (1979) were the first to suggest that, for the treatment of CDN, only the underlying damaged cartilage may need to be removed.<sup>5</sup> In this procedure, a skin flap is developed in order to lower and smoothen the cartilage edges. The goal of this procedure is to minimize pressure on the skin overlying the cartilage skeleton during sleep. Subsequently, further studies elaborating on this treatment principle showed, in a total of 64 ears, cure rates of at least 80 per cent and excellent cosmetic results.<sup>2,3</sup>

This article outlines our contribution to the literature, describing the results of our experience with this technique.

### Patients and methods

We traced the records of 34 patients (18 men and 16 women) with an average age of 56 years (range 21-84 years) who were operated upon for chondrodermatitis nodularis helicis (24) or anthelicis (13) between 1991 and 2001. All patients received a shave biopsy under local anaesthesia (lidocaine one per cent with adrenaline 1:100 000) for histological confirmation and to exclude a skin malignancy. In our group of 34 patients, two patients had had their lesions surgically treated previously by their family practitioner, and two other patients, aged 21 and 26 (the youngest patients of our group), developed CDN after previous cosmetic otoplasty for protruding ears. All lesions had been managed previously with injection of Kenakort-A40®.

All patients were operated upon by the senior author (HDV). The technique of this procedure is depicted in Figures 1 and 2. After local anaesthesia (a mixture of marcaine 0.5 per cent with adrenaline 1:2000 000 and lidocaine one per cent with adrenaline 1:100 000) a skin flap is raised. Then, the damaged cartilage is removed and the edges rounded. After ensuring that all the cut cartilaginous edges are smooth, the skin flaps are placed back. Mattress-suturing is performed to prevent haematoma formation.<sup>9</sup> The procedure permits full visualization of the cartilage, so resection with smoothing of the edges is easily achieved.

The long-term effectiveness of the cartilage excision procedure was assessed by a retrospective study of the medical reports and by means of a telephone interview. The main outcome measure was the

presence or absence of discomfort compared to that prior to surgery. All patients were offered a clinic visit if they so desired.

### Results

All 34 patients were symptom-free at least three months post-operatively according to their medical report. Seventeen patients with 19 CDN lesions were interviewed by telephone. The other 17 patients could not be reached. Five of these patients were deceased.

Of the 37 lesions that were treated, 34 (91.9 per cent) remained symptom-free, with a mean follow-up period of 30.7 months (range three to 111 months). Only one recurrence (2.7 per cent) had occurred. Although much improved after surgery, two patients described discomfort in the area of the previous CDN lesion, but without obvious recurrence of the lesion itself. These patients did not feel that there was a need for revision surgery. It was noteworthy, that the latter two patients were identified as a result of the telephone call and not as a result of renewed referral by the patient's general practitioner.

### Discussion

This article challenges the traditional proposed aetiology of CDN. Our paradigm involves a pressure-induced, sterile chondritis. Subsequent skin manifestations may be considered a secondary phenomenon. This proposition suggests a surgical technique that focuses on cartilage lowering and smoothing to reduce the pressure on the overlying skin. Lawrence,<sup>2,8</sup> and Cheilly and Lillis,<sup>5</sup> should be given credit for their studies on a surgical treatment modality for CDN that follows this principle. Using the technique, which is described in this article, they found a success rate of 90 per cent and 70 per cent for the helical and anthelical lesions respectively. Our results support their findings.

We traced the medical reports of 34 patients with 37 CDN lesions who were treated for CDN by removing the underlying cartilage alone. All patients were symptom-free at least three months post-operatively. Discomfort was still present in two cases (5.4 per cent), while only one true recurrence (2.7 per cent) had occurred with a mean follow-up period of 30.7 months. The latter patient was one of our first patients whom we treated with the described technique. Eight months after the first operation she was re-operated upon for the recurrence (using the same principles and technique). Currently, after more than seven years of follow-up, she is still symptom-free.

For otolaryngologists wedge resection is the treatment of choice for CDN. This is reflected in the Dutch Otolaryngology/Head and Neck Surgery training program. Our past experience yielded a 10 per cent recurrence rate with this relatively simple technique. Although these results are good, ear deformity did sometimes occur, in particular in cases of repeated surgery. With a paradigm change on the

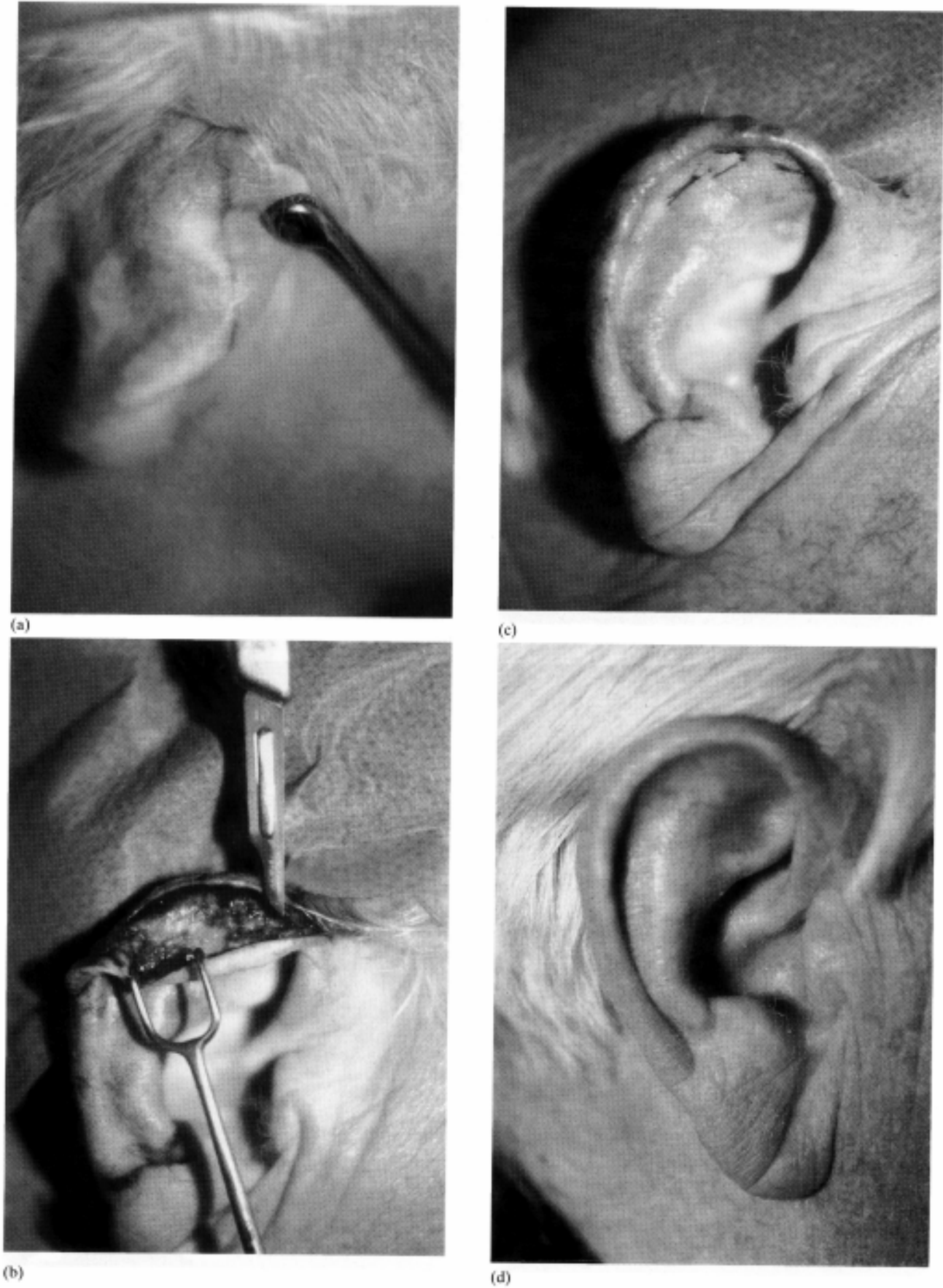
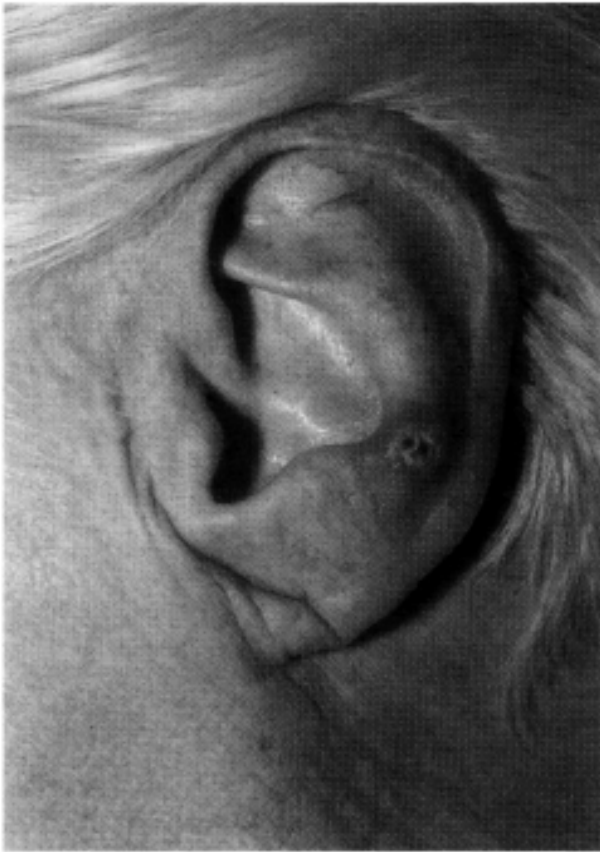
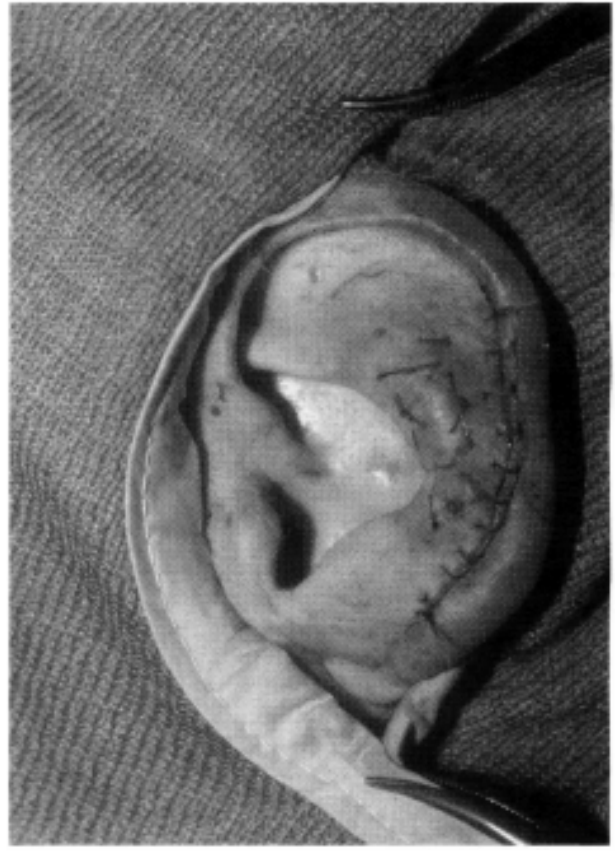
FIG. 1

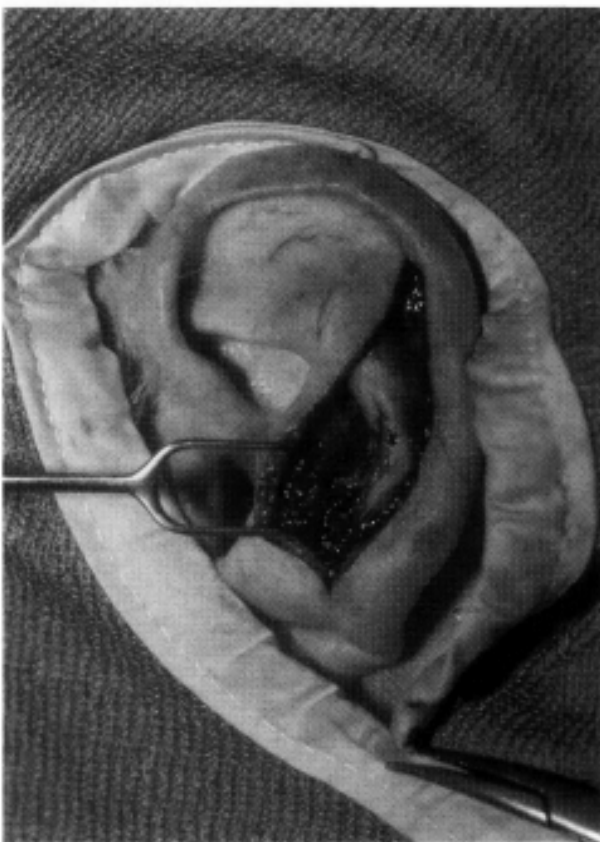
Chondrodermatitis nodularis; treatment of the helix, (a) incision line is drawn on right helix (dorsal view); (b) smoothing of the underlying cartilage after a skin flap has been raised; the original skin lesion is not removed; (c) mattress-suturing to prevent haematoma formation; (d) result after three months.



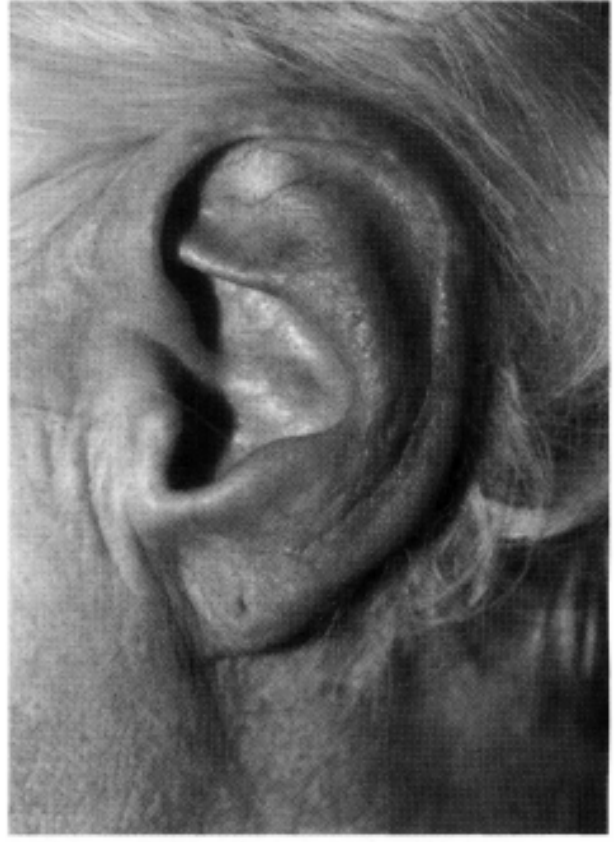(a)



(c)



(b)



(d)

FIG. 2

Chondrodermatitis nodularis; treatment of the anthelix. (a) lesion left anthelix; (b) smoothing of the underlying cartilage after a skin flap has been raised; the original lesion is not removed; (c) mattress-suturing to prevent haematoma formation; (d) result after three months.

aetiology of CDN we have completely abandoned wedge resections and now almost exclusively perform the cartilage removal technique as was described above.

In conclusion, Chondrodermatitis nodularis helioides or antheloides is a common lesion, that is often seen and treated by otolaryngologists. The dermatological literature has presented us with an alternative therapy to wedge excision, the technique described in this article, which consists of removal of the underlying cartilage alone. This technique combines low recurrence rates with only minor changes in the outer aspect of the pinna.

#### References

- 1 Zuber TJ, Jackson E. Chondrodermatitis nodularis chronica helioides. *Arch Fam Med* 1999;**8**:445-7
- 2 Lawrence CM. The treatment of Chondrodermatitis nodularis with cartilage removal alone. *Arch Dermatol* 1991;**127**:530-5
- 3 Hudson-Peacock MJ, Cox NH, Lawrence CM. The long term results of cartilage removal alone for the treatment of Chondrodermatitis nodularis. *Br J Dermatol* 1999;**141**:703-5
- 4 Munnoch DA, Herbert KJ, Morris AM. Chondrodermatitis nodularis chronica helioides et antheloides. *Br J Plast Surg* 1996;**49**:473-5
- 5 Ceilley RI, Lillis PJ. Surgical treatment of Chondrodermatitis nodularis chronica helioides. *J Dermatol Surg Oncol* 1979;**5**:384-6
- 6 Coldiron BM. The surgical management of Chondrodermatitis nodularis chronica helioides. *J Dermatol Surg Oncol* 1991;**17**:902-4
- 7 Taylor MB. Chondrodermatitis nodularis chronica helioides successful treatment with the carbon dioxide laser. *J Dermatol Surg Oncol* 1991;**17**:862-4
- 8 Lawrence CM. Surgical treatment of Chondrodermatitis nodularis. In: Robinson JK, Arndt KA, Leboit PE, Wintroub BU. *Atlas of Cutaneous Surgery*, Philadelphia: W. B. Saunders Company, 1996, 201-6
- 9 Vuyk HD, Bakkers EJM. Absorbable mattress sutures in the management of auricular hematoma. *Laryngoscope* 1991;**101**:1124-6

Address for correspondence:

H. D. Vuyk,  
Department of Otolaryngology/Facial Plastic and  
Reconstructive Surgery,  
Ziekenhuis Gooi Noord,  
Rijksstraat 1,  
1261 AN Blaricum,  
The Netherlands.

Fax: 00 31 355391675 E-mail:  
j.a.deru@kmb.azu.nl

---

Dr J. de Ru takes responsibility for the integrity of the content of the paper.

Competing interests: None declared

---