Clin. Otolaryngol. 1996, **21,** 106-118

Augmentation mentoplasty with solid silicone

H.D.VUYK

Department of O tolaryngology j Facial Plastic Reconstructive Surgery, Ziekenhuis Gooi Noord, Blaricum, the Netherlands

Accepted for publication 27 January 1995 VUYK H.D.
(1996) *Clin. Otolaryngol.* 21, 106-118

Augmentation mentoplasty with solid silicone

Chin retrusion is important to the facial plastic surgeon, as it is a commonly encountered defect in patients seeking rhinoplasty. Careful pre-operative evaluation may identify patients who could benefit from concurrent augmentation mentoplasty. Augmentation mentoplasty using pre-formed silicone implants, placed sub-periosteally using an extraoral approach in a total of 40 patients were studied. The procedure proved to be relatively straightforward, rewarding and associated with very little morbidity. Hard silicone appears to be a reliable and safe implant material for augmentation mentoplasty in terms of host tolerance, including infection. There were no clinical side-effects from the minimal bone resorption which could be noted in eight out of 13 patients studied radiographically. Keywords *augmentation mentoplasty silicone bone resorption*

Facial beauty results from symmetrical and harmonious proportion.[1] Chin retrusion may detract from an otherwise aesthetically pleasing facial profile. The 'weak' chin-mandibular complex suggests a lack of character strength—a deficiency in forcefulness.[2,3] Chin retrusion is of importance to the facial plastic surgeon as it is a commonly encountered defect in patients seeking rhinoplasty.[4,5] Many patients are, however, unaware of the defect as part of their facial imbalance.[4,6,7] Patients with a retruded chin who are seeking rhinoplasty may be counselled not only with respect to the nasal profile, but the whole facial profile including the chin can be taken into consideration in order to improve the result of surgery and enhance patiënt satisfaction.

A variety of autografts, homografts and implant materials have been used for chin augmentation in the past. Nowadays, silicone implants are used most frequently.[7] We review our 4 year experience with preformed silicone implants, placed subperiostially using an extraoral approach in a total of 40 patients.

Evaluation

The patiënt is studied seated. The profile, front view, and both diagonal views demand attention. Normally the anterior projection of the mentum remains 1-2 mm posterior to the plane of the lower lip vermilion border, while the patiënt's head is in the Frankfurt position[2,6,8,9] (Figure 1).

The perceived adequacy of chin projection depends also on the chin's relationship with other facial features, such as subnasal contour, relative lower-facial-third height and relative facial mass and shape.[10] Moreover, the patient's sex and height does play a role. A less protruding chin is acceptable in females

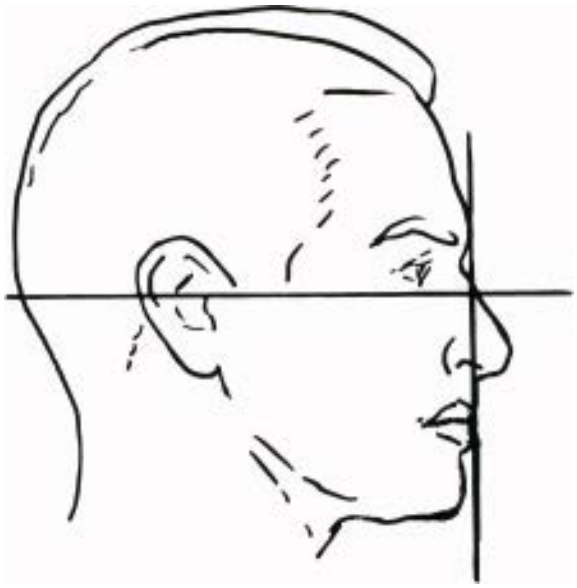

Figure 1. Ideal anterior projection of the mentum depicted with the patient's head in the Frankfurt position.

Correspondance: Dr H.D. Vuyk, Department of Otolaryngology/Facial Plastic Reconstructive Surgery, Ziekenhuis Gooi Noord, Rijksstraatweg l, 1261 AN Blaricum, the Netherlands.

and small persons. Not only the profile aspects of the facial soft tissue should be considered, but the anteroposterior (A-P) contours need attention as well. The amount of augmentation needed to move the soft tissues of the chin laterally in order to blend the chin into the mandibular line and cheek, should be estimated in the A-P view. The chin width should be appropriate to the width of the patiënt's face. Any facial and mandibular asymmetry should be noted. Clinical assessment further yields specific information about lip posture, the depth of the labial mental sulcus and mentalis muscle activity and hypertrophy, especially with the patiënt smiling.

Careful palpation of the mandible and chin is essential. Palpation defines the angle of inclination of the mandible while delineating the degree of prominence of the symphysis and mental protuberance.[3] The pre-operative evaluation includes Standard full-face, lateral, oblique, sub-mental and intra-oral photographs. Ideally, this can be supplemented by cephalometric roentgenograms. The actual chin retrusion and the possible benefit of surgery may clearly be demonstrated to the patiënt using computer imaging techniques (Figure 2).

It is of importance to distinguish between functional and aesthetic problems. When functional problems associated with malocclusion exist, the occlusion must be treated. Classification of the retruded chin does facilitate patiënt selection and treatment planning. The two main categories of retruded chin are microgenia and retrognatia. Microgenia is a localized under-development of the mandibular symphysis with normal (class I) occlusion. Retrognatia is characterized by a retruded mandible, resulting in class II malocclusion.

Figure 2. Computer imaging demonstrates possible change after augmentation mentoplasty and concurrent rhinoplasty. (See also figure 8).

Treatment

Microgenia, with a relatively normal lower-facial third height and normal or near normal occlusion can be corrected by implant insertion or sliding osteotomy. Patients with a short facial profile may not be goód candidates for augmentation with implants. They may have a deep sub-labial crease, which, in combination with lower lip redundancy, may be compounded by augmentation of the chin.[5] Generally speaking, more extensive orthognatic surgery can be of benefit for patients with very short or tall lower facial height and for more complex disproportions like retrognatia. Most patients seeking rhinoplasty with a retruded chin will see the benefit of a relatively simple chin augmentation procedure. However, confronted with more extensive orthognatic surgery, including sliding osteotomy, many reject such treatment.

Implant characteristics

The ideal material for augmentation mentoplasty should have a 'natura!' consistency, mould well to the mandible and result in minimal morbidity. It should be easily shaped and secured. It should be able to resist possible future trauma. A multitude of materials, autografts, homografts and alloplasts have been used over the years. However, during the last 10-15 years alloplasts have gained wide acceptance because of their ready availability, lack of donor site morbidity and relative good post-operative tissue tolerance.[9]

Solid silastic (silicone rubber), which was introduced in the 1950s, is one of the most widely used alloplastic materials in augmentation aesthetic surgery. Silicone rubber is firm but flexible, highly resistant to changes in body temperature and it can be repeatedly autoclaved without change in its consistency or physical properties. In addition, it is inert and relatively non-reactive to body tissue fluids and does not become absorbed or calcified, or undergo degeneration.[11] For augmentation mentoplasty preformed solid silastic prostheses of various sizes and shapes are available. Two types were used in this study. For smaller to moderate augmentation a solid type implant was used (Figure 3). When more central height was needed and it was desirable to blend the lateral mandibular region into the cheeks, a longer, extended type implants was used (Figure 4). If necessary, these silicone implant can be carved and tailored to the patiënt's needs. Most implants do have a midline marking to facilitate inser-

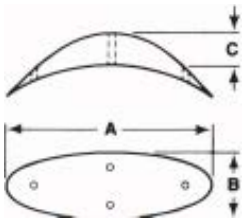

Figure 3. Solid silicone implant.

tion and also have perforations for fibre ingrowth to improve fixation.

In determining the size and shape of the implant for the individual patiënt we rely on palpation as well pre-operative life-size photographs with the face positioned in the Frankfurt plane and in resting occlusion with the lips gently touching.[12] One should bear in mind that implant height and soft-tissue projection do not have a 1:1 relationship. A 70% gain in soft-tissue projection after implant should be accounted for.[13] Caution should be exercised not to overaugment the recessed chin, thereby avoiding an unaesthetically surgically looking knob-like chin with over-accentuated transition to the margin of the mandible and unattractive deep labiomental crease.

Technique

Operations were performed under general anaesthesia when combined with rhinoplasty. Local infiltrative anaesthesia with l % lidocaine/1:100 000 epinephrine combined with marcaine 0.5%/ 1:200 000 epinepherine was used. In two patients mentoplasty was performed as the only procedure using regional block, local infiltration anaesthesia combined with I.V. analgesia and sedation. Mentoplasty, when combined with rhinoplasty was performed first to minimize the contamination with Instruments and gloves. For the same reasons all patients received one intravenous dose of prophylactic antibiotic l h bef ore the operation (Floxapen 1000 mg).

The midline, labiomental sulcus, mental nerve, and submental creases are marked with the patiënt sitting up before injecting the local anaesthesia (Figure 5). The patiënt is asked to flex at the neck and the submental crease is determined by pinching the chin and submental region together. A small incision just posterior to the sub-mental crease is made extending 1/2-1 cm to either side of the mid-line. To stagger the incision line, dissection is subsequently deepened through the subcutaneous tissues at a more superior level until the inferior border of the mandible is encountered. Then the periosteum is incised at the lower symphysis for 2 1/2 cm. With subperiosteal sharp dissection using a Freer elevator medially and blunt type scissors laterally, a pocket is made to accommodate the implant. The pocket should be made just large enough to prevent the implant shifting and doubling up if the pocket is too small. As the mental nerve orifice is rarely closer to the midline than 27 mm[2] the pocket for a solid implant will not reach the mental nerves laterally. If an extended implant is used the pockets do reach more laterally, but remain inferior to the foramen of the mental nerves. For both types of prosthesis the pocket should not reach higher than the labial mental sulcus. It is important to maintain the fibrous attachment of soft tissues to the lower border of the mandible throughout the majority of the subperiosteal pocket. This prevents inferior implant displacement into the neck. Haemostasis is achieved and the pocket irrigated with gentamycin solution.

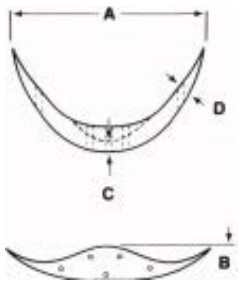

Figure 4. Extended silicone implant.

The implant which has also been soaked in gentamycin is inserted beneath the periosteum. The implant is positioned on the progonion where the bone is dense. By close inspection, including looking from the head of the patiënt downward and palpation the implant is checked for symmetry and midline position. The blue mid-line on the implant is used as a reference. If necessary, the implant is secured to the periosteum with 4-0 prolene sutures. Closure is in layers. 4-0 and 5-0 PDS are used for deep soft tissue and subcutaneous sutures. Wound edges are precisely approximated using 5-0 or 6-0 prolene. A chin dressing consisting of leucoplast porous tape remains in place for 5-6 days.

Material and methods

A series of 40 patients who underwent augmentation mentoplasty between January 1990 and 1994 were studied retrospectively. This series consisted of 11 men and 29 women, varying in age from 19 to 50 with a mean of 28 years. The follow-up period was 1-45 months with a mean of 15 months. Two types of hard silicone implants were used: 30 solid implants and 10 extended implants (McGhan). Implant height varied from 4 to 8 mm.

One extended implant was shortened laterally to facilitate insertion. Another four implants were carved in either a horizontal or vertical dimension. Furthermore, the height of one chin implant (7 mm) was further enhanced by placing a 2 mm silastic wafer under the mid-portion of the implant. This wafer was sutured to both the implant and periosteum. In a second

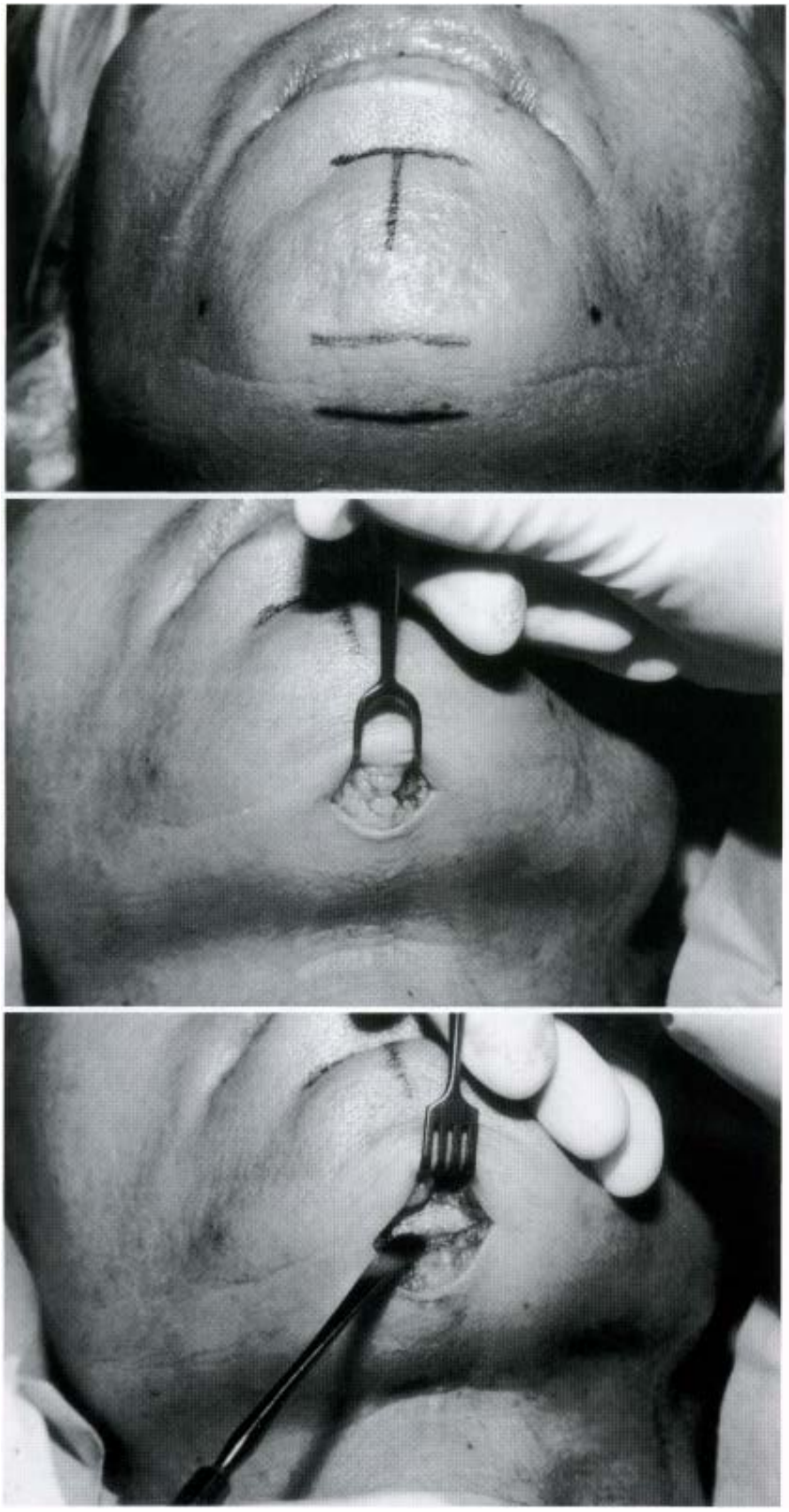

(a)

(b)

(c)

Figure 5. Operation sequence: (a) pre-operative marking identifying melo-labial sulcus, midline, caudal mandibular border, proposed submental incision and both mental nerve foraman; (b) after regional block of mental nerves and local infiltrative anaesthesia, the submental incision is made through subcutaneous fat; (c) cephalic retraction of the tissues allows subsequent staggered incision through to periosteum. Sub-periosteal pocket formation using elevator is shown; (d) insertion of a solid silicone implant; (e) fixation with permanent sutures (if necessary); (f) layered closure.

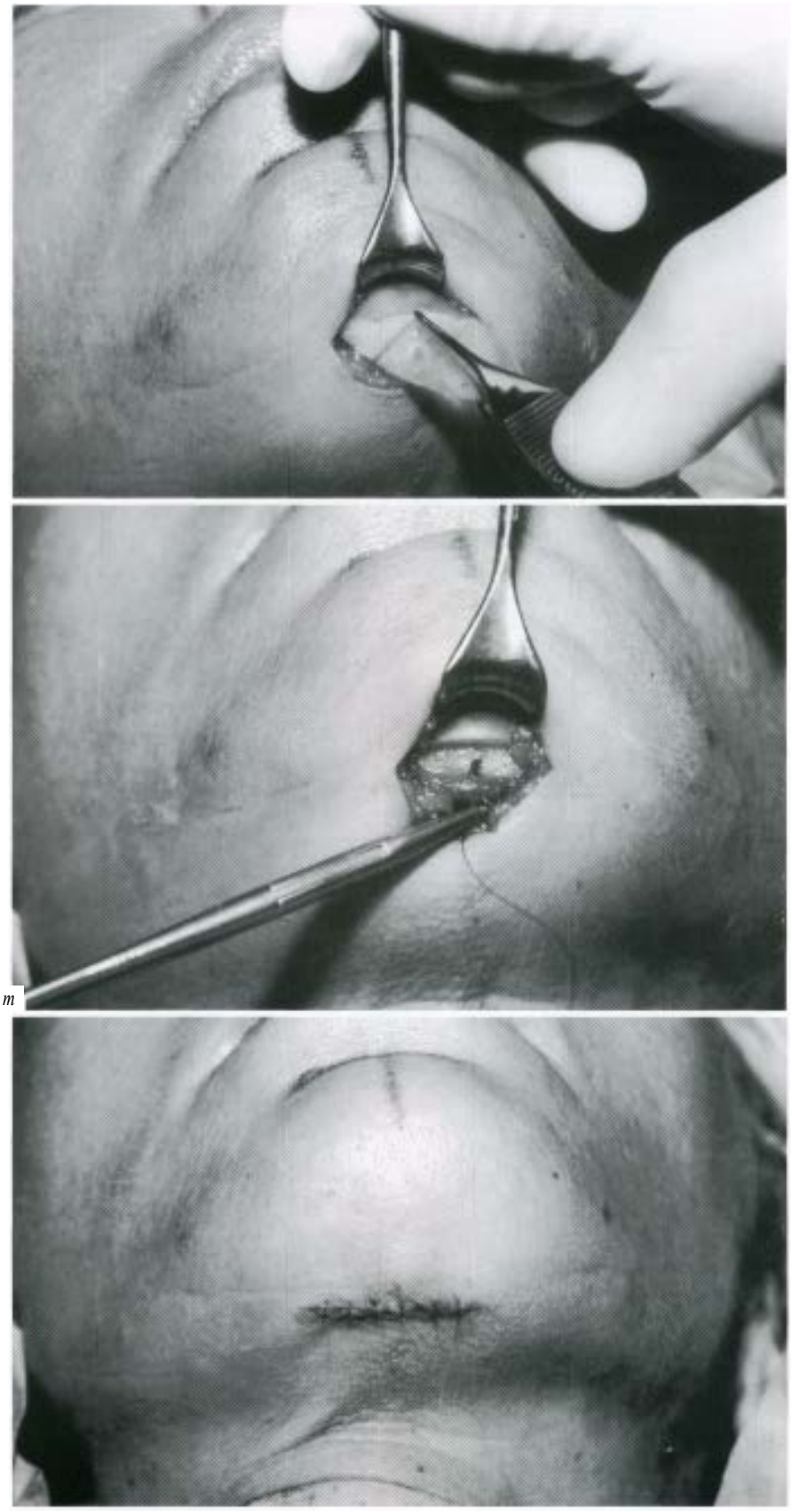

(d)

(e) *m*

(f)

Figure 5. *(Continued).*

patiënt profile correction was improved by inserting a goretex 2 mm soft tissue patch (W.L. Gore & Association, Livingston, UK) between the solid implant (height 8 mm) and the mandible. Augmentation mentoplasty was performed in combination with rhinoplasty in 38 patients, including one who underwent concomitant liposuction. In one patiënt a malpositioned solid type prosthesis (operated upon elsewhere) was exchanged for an extended type. One other patiënt underwent augmentation mentoplasty alone. Of a total of 400 rhinoplasties performed in the study period, 10% was performed in combination with chin augmentation. Lateral mandibular radiographs were available in 13 patients with nine solid and four extended implants and a follow-up of 8-45 months with a mean of 20 months.

Results

Uneventful and rapid healing occurred in all patients. By palpation all implants were firmly attached to the mandible. There was no clinical evidence of mandibular destruction. In three patients (7%) a certain degree of asymmetry was noted. In two patients the implant was off mid-line. One of these two did accentuate a pre-existing mandibular asymmetry. In a third patiënt an implant was noted to be tilted in the horizontal plane, needing a revision procedure with carving of the implant. Overall, this has been the only patiënt of this series of 40 patients in need of a secondary procedure.

Over-correction was not noticed. In none of the patients was the labiomental sulcus over-accentuated at the cost of a more anterior projecting chin. Lateral mandibular views of one out of 13 patients studied radiographically did show slight bone absorption (Figure 6). In seven patients minimal bone absorption up to 1 mm could be noted. In five patients the normal lateral bony contour was intact.

After one revision all patients were pleased with the result (Figures 7 and 8). All thought the implant feit 'natural' and 'a part of them' indicating satisfactory stability.

Complications

None of our patients developed signs of infection. None of the implants was extruded. Post-operative paraesthesia was noted in a few patients which proved transient. On inspection the submental scar was hardly noticeable and never a problem to the patiënt. Two patients developed submental hae-matomas and bruising with no long-term sequelae. One admit-ted aspirin use in spite of pre-operative counselling in this respect.

Discussion

It is striking that most patients seeking rhinoplasty, who have a retruded chin are unaware of the defect. This was noted by Aufricht[14] and has subsequently been confirmed by many others.[15] The reason may be that augmentation mentoplasty lacks the widespread publicity that other procedures, such as rhinoplasty and rhytidectomy have enjoyed. It must be stressed that a retruded chin may accentuate nasal projection and detract from an otherwise aesthetically pleasing facial appearance. In other words, a well proportioned nose requires the balance of a proportioned chin to achieve the fullest aesthetic impact. Chin augmentation may not only improve facial balance and proportion, but less reduction rhinoplasty surgery may be needed for a satisfactory result. In our opinion, chin augmentation may set the stage for more predictable and safer rhinoplasty surgery in some patients. In general it is unwise and unethical to suggest an operation to correct a defect of which the patiënt is unaware, but augmentation mentoplasty may be the exception to the rule. For all the above reasons, we do recommend augmentation mentoplasty to patients if hè or she could benefit to bring more harmony to the face. Proper patiënt education enhanced by photographs, computer imaging and patiënt brochures[16] will lead to understanding about the surgery to be performed. To negate any financial benefit by proposing additional surgery, we do not charge for chin augmentation when rhinoplasty is being performed.

Evaluation of the ideal chin position is facilitated using standardized life-size photographs, taking into account a number of patiënt characteristics like sub-nasal contour, relative lower-facial third height, relative facial mass and shape,[10] as well as the patient's sex and height. Subsequently implant size and shape are determined. A 70% soft tissue projection gain may be anticipated because of redistribution and circumferential displacement of the soft tissues as well as posterior implant settling into the mandibular bone, contributing equally to this phenomenon.[13] Depending on the individual patient's chin characteristics and a pre-operative estimate of the amount of augmentation needed, pre-fabricated silicone implants are chosen with respect to height, width and depth. The majority of patients with chin retrusion rarely require more than a slight increase in volume.[5,11] Most often a 3 or 5 mm solid type prosthesis is adequate. Larger protheses should extend more laterally to avoid depressions on either side of the implant with a concentrated appearance of the chin.[2,5] However, large size implants do risk labiomental sulcus alteration and bone absorption.[17]

Given the limited number of different implants available, intraoperative modification of the implant by carving and contouring helps to produce a good result. Extension wafers[18] do enhance the surgeon's armamentarium. The use of a wafer (silastic or goretex) placed under the implant fixed with sutures can produce the exact amount of augmentation required. Moreover, extension wafers eliminate the trial-and-error technique and its added manipulation and trauma associated with utilization of sizers, implant change and additional pocket enlargement.

Various materials are available for augmentation men-

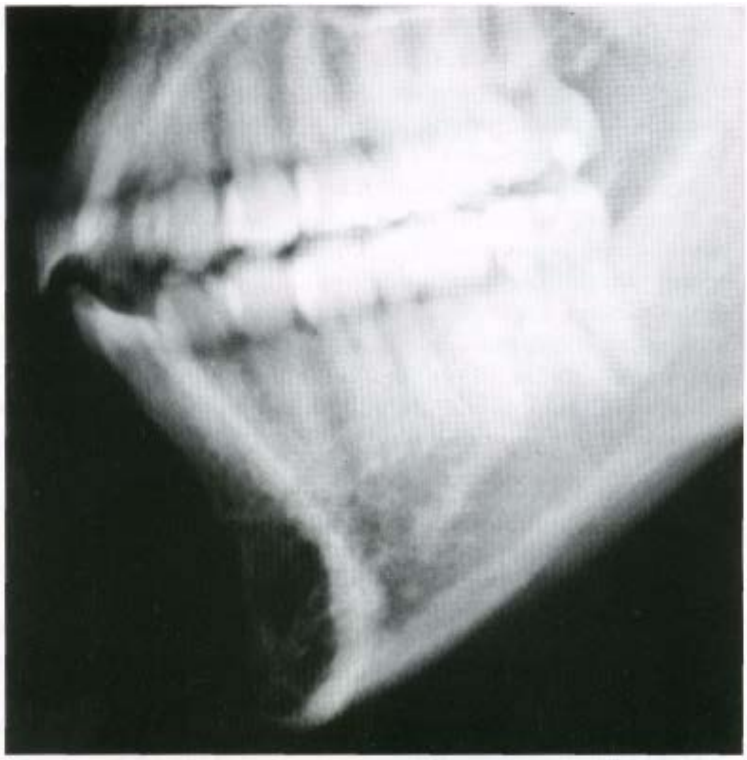

Figure 6. Maximum amount of settling of the implant with bone absorption seen in one patiënt with solid type implant after follow-up of 27 months.

toplasty. In the past many surgeons have used autografts. Autografts proved difficult to mould to the mandible and difficult to secure in position. Moreover, the harvesting of large volume autografts adds significant morbidity to the procedure. Homografts are more easily available. However, a significant amount of autogenous" and homologous grafts[19] are resorbed because of the strong moulding forces placed on such grafts by the constant mobility and pressure of the overlying soft tissues." During the past 15 years, allografts have become the material of choice.[9,20-21] In a survey of more than 10 000 mentoplasty procedures performed by over 90 surgeons solid silicone rubber was found to be by far the most popular type of implant.[7] In comparison to Mersilene mesh, Proplast and Acrylic, solid silicone rubber was associated with the lowest overall complication rate (2.7%), including infection (1.7%) and extrusion (0.3%).[7] Because implants like Supramid, Mersilene and Proplast do develop tissue infiltration, they can be quite difficult to remove if necessary. Solid silicone is much easier to slip out of an infected pocket. In view of the fact that our own series consists of the first 40 mentoplasties performed by the author, our study confirms the relative safety and efficacy of solid silicone for augmentation mentoplasty.

In this series the external, sub-mental approach was used for its ease of technique and minimal morbidity. The small but often inconspicuous sub-mental scar was well accepted by the patients. Positioning of the incision just behind and not in the sub-mental crease proved beneficial. We chose not to use the endoral approach because of the disadvantage of suture line irritation,[22] especially in patients with a dental prosthesis, and a slightly higher infection rate[7,9] compared with the external approach. However, both routes of insertion can poten-tially obliterate the labiomental sulcus if the implant is mal-positioned or too large.

In this series no implant was extruded and no infection was encountered. In the mental area there is a moderate amount of soft tissue to cover the implant material. This may explain the infrequency of problems with host rejection and with extrusion. Any evidence of infection or extrusion should be treated conservatively at first, before removal of the implant.[5] Haematoma proved uncommon and is best left alone to absorb. Temporary anaesthesia was frequently reported immediately after the operation. This was thought to be secondary to soft tissue oedema and surgical manipulation. It is remarkable that even with a more difficult extended dissec-tion caudal and lateral to the mental nerve for extended implants no permanent mental nerve injury was noted in this series.

Implant malposition with asymmetry was noted in one out of 40 patients. For prevention, the implant pocket size is critical. An excessively large or asymmetrical pocket may risk excentric implant position. If the recipiënt site is too small, the prosthesis will not be flat upon the mandible, and the implant ends will shift and roll upon themselves producing an abnormal contour. Sub-periosteal pockets do seem to produce a dense tissue covering firmly confining the implant to the

Figure 7. A. A patiënt who is self-concious about her nasal dorsal hump.

Figure 7. **B.** Postoperative situation l year after rhinoplasty in combination with augmentation mentoplasty using a solid type implant.

Figure 8. A. Patiënt requesting augmentation rhinoplasty.

Figurc 8.**B.** Ten months aftcr rhinoplasty and augmcntation menloplasty using a solid type implant.

pocket. However, differences between supra- and sub-periosteal positioning with respect to implant malpositioning was not confirmed in the review by Scaccia.[7] Although not noticed in this series, malposition may be somewhat more frequent with the extended type prosthesis compared with solid type prosthesis.[7] For the extended prosthesis more dissection is necessary and insertion of the prosthesis with its flimsy end is more difficult compared with solid implants. However, we have shortened the extended anatomical prosthesis in one in 10 cases to facilitate insertion and secure positioning.

Bone absorption could be noted in eight out of 13 patients radiologically studied. Most absorption was over the cephalic part of the implant overlying the supragonion. Only in one patiënt was the maximum amount of settling more than l mm. Bone absorption with subsequent loss of correction was not noticed in the series. Admittedly, we do not have pre- and post-operative cephalometric measurements and radiological views of all patients. It should be stressed that implant position and size is of particular clinical importance with respect to bone absorption. In this series all implants were placed over the pogonion. The pogonion with its thicker bone is more resistant to absorption than suprapogonion where the man-dibular cortex is thin.[23] Although bone absorption is well documented radiographically, there is little evidence of peri-dontal destruction or loss of vitality of the anterior teeth. One tooth was reportedly lost in a total of over 10000 cases.[7] Whether supra- or sub-periosteal placement of implants influence the risk of bone absorption, remains controversial.[24] There is some evidence, however, that less mandibular cortical resorption occurs when the implant is placed over the peri-osteum and the blood supply of the bone remains intact.[25] However, it seems logical to assume that the differences between sub- and super-periosteal insertion of implants in this respect is accentuated by larger sized implant. Generally speaking over-sized implants (for the soft tissue coverage available) do sustain more mentalis muscle strain increasing the risk of subsequent implant resorption.[7,26] However, bone resorption seems to be self-limiting, most of the posterior drift or settling will take place during the first 6-12 months[26] until it stabilizes within 2 years after implantation.[13] * Compared with augmentation mentoplasty using implants, sliding genioplasty is a procedure of higher morbidity compared with implants.[22,27] The sliding genioplasty takes increased surgical time[7] and a longer healing period. It has increased risk of mental ncrvc and tooth injury[7] and possiblc post-operative notching of the mandibular ra mus where the horizontal scgments are advanced.[3] However, labiomental sul-cus depth may be better maintained[2]* with sliding genioplasty because the maximum amount of augmentation lies at a lower level. As with augmentation mentoplasty, the soft tissue changc by horizontal osteotomy will also bc about 70% of the hard tissue advancement.[29] However, it should be con-sidered in patients with excess or insufficient vertical mandibular height or mandibular asymmetry.

Acknowledgement

I would like to thank Dr R.B. Greebe, orthognatic surgeon for his critical review of this study.

References

1 TOLLETH H. (1987) Concepts for the plastic surgeon from art and sculpture. *Clin. Plast. Surg.* 14, 585-598

2 WEBSTER R.C., WHITE M.F., SMITH **R.C.** *et al.* (1977) Chin augmentation: subperiostial and supraperiosteal implants. *Aesth. Plast. Surg. l,* 149-160

3 FLOWERS R.S. (1991) Alloplastic augmentation of the anterior mandible. *Clin. Plast. Surg.* 18, 107-138

4 DAVIS P.K.B. (1983) Chin augmentation with rhinoplasty: a tutorial dissertation. *Br. J. Plast. Surg.* **36,** 204-209

5 SZACHOWICZ E., KRIDEL R.W. (1987) Adjunctive measures to rhinoplasty. *Otolaryngol. Clin. North. Amer.* 20, 895-910

6 WANG T.D., COOK T.A. (1987) A ten year review of proplast augmentation mentoplasty. Read before the Amer Acad of Facial Plastic and Reconstructive Surgery. Spring meeting, Denver, Colorado

7 SCACCIA F.J., ALLPHIN A.L., STEPNICK D.W. (1983) Com-plications of augmentation mentoplasty: a review of 11095 cases. *Int. J. ofAest. Rest. Surg.* l, 3-8

8 POWELL N., HUMPHREYS B. (1984) Proportions of the aesthetic face. New York Thieme-Stratton Inc. *Amer. Acac. Facial Plast. Reconstr. Surg.*

9 McCoLLOUGH E.G., HOM D.B., WEIGEL N.T., ANDERSON J.R. (1990) Augmentation mentoplasty using mersilene mesh. *Arch. Otolaryngol. Read N eek Surg.* 116, 1154-1158

10 GIBSONF.B.,CALHOUN K.H. (l992) Chin position in profile analy-sis, comparison of techniques and introduction of the lower facial triangle. *Arch. Otolaryngol. Head&Neck Surg.* 118, 273-276

11 LA WSON W., SALITAN M.L. (1991) Mentoplasty. I n Aesthetic facial surgery, pp 735-755. *Lippingcot Comp.* Philadelphia

12 ZYLKER T.D., VUYK H.D., ADAMSON P.A. (1992) Rhinoplasty: preoperative photography. *Clin. Otolaryngol.* 17, 361-369

13 KENT J. (1981) Chin and zygomatico maxillary augmentation with Proplast. *J. Oral Surg.* **39,** 912-919

14 Aui'RKTiT G. (1934) Combined nasal plastic and chin plastic: correction of microgcnia by osteocartilagenous transplant from large hump nose. *Amer. J. Surg.* 25, 292

15 SIMONS R.L. (1975) Adjunctive measures in rhinoplasty. *Otolaryngol. Clin. North Amer.* 8, 717

16 VUYK H.D., ZYLKER T.D. (1995) Psychosocial aspects of patiënt selection: a surgeon's perspective. Facial Plastic Surgery Quarterly Monographs 11, 55-60

17 ADAMS J.S. (1987) Grafts and implants in nasal and chin augmentation. *Otolaryngol. Clin. North Amer.* 20, 913 930

18 GLASGOLD A.I., GLASGOLD M.J. (1994) Intraopcrativc custom contouring of the mandible. *Arch. Otolaryngol.* 120, 180 184

19 SciiULLiiR D.E., BAKDACII J., KRAUSIÍ C.J. (1988) Irradiatcd homologouscartilagegraft. Longterm rcsulls. *Arch. Ololaryngol. Head & Neck Surg.* 114, 291 295

20 PAKKS M., CANODIA R. (1980) Helpl'ul hints in augmenlalion mentoplasty. *Larytu/oscope* **90,** 1740 1743

21 BiiiiKiiuis G.J. (1984) Augmentation mentoplasty with polyamide mesh. *Arch. Orolaryngol.* 100, 364 367

22 SILVER W.E. (1993)Chin and malaraugmentation. *lleaüaiutNeck Surg. Otolaryngol.,* pp 2284 2298. Lippingcott Comp. Philadelphia

23 FRIEDLAND J.A., COCCAKO P.J., CONVÜRSI; J.M. (1976) Retro-

spective cephalometric analysis of mandibular bone absorption under silicone rubber chin implants. *Plast. Reconstr. Surg.* 57, 144-151

24 LILLA J.A., FISTNUS L.M., JOBE R.P. (1976) The long term effects of hard alloplastic implants when put on bone. *Plast. Reconstr. Surg.* 58, 14-18

25 PARKS M. (1973) Avoiding bone resorption under plastic chin implants. *Arch. Otolaryngol.* 98, 100-101

26 SPIRA M. (1973) Editorial addenda. *Plast. Reconstruc. surg.* 51, 174

27 REIS T.D. (1973) Editorial addenda. *Plast. Reconstruc. surg.* 51, 174-175

28 GALLAGHER D.M., BELL D.H., STORUM K.A. (1984) Soft tissue changes associated with advancement genioplasty performed con-comitantly with superior repositioning of the maxilla. /. *Oral Maxillofac. Surg.* 42, 238-242

29 MCÜONALD J.P., McNEiLL R.W., WEST R.A. (1977) Advancement genioplasty: a retrospective cephalometric analysis of oss-eous and soft tissue changes. /. *Oral Surg.* 35, 640-647