

REVIEW

Mohs micrographic surgery for facial skin cancer

H.D. VUYK & P.J.F.M. LOHUIS*

Department of Otolaryngology, Facial Plastic and Reconstructive Surgery, Gooi Noord Hospital, Blaricum, The Netherlands

Accepted for publication 2 April 2001

VUYK H.D. & LOHUIS P.J.F.M.
(2001) *C/m. Otolaryngol.* 26, 265-273

Mohs micrographic surgery for facial skin cancer

Although it is well established that conventional treatment modalities generally result in high cure rates for non-melanoma skin cancer, it has been demonstrated over recent decades that the highest overall cure rates are achieved using Mohs micrographic surgery. The key to Mohs surgery is the excision and control of complete peripheral and deep resection margins in one plane, allowing orientation, mapping and re-excision of microscopic tumour extension. These extensions can be followed without sacrificing inappropriate amounts of normal tissue, yielding high cure rates and maximum preservation of tissue. These qualities make Mohs surgery an important and reliable treatment for skin cancer of the face, in particular when it concerns large, aggressive or recurrent carcinoma in cosmetic and functionally important areas. In an 8-year study period, 369 basal cell carcinomas (BCCs) and 56 squamous cell carcinomas (SCCs) of the face were treated in our department using Mohs surgery. With a follow-up ranging from 3 months to 99 months (mean 33 months), none of the BCCs recurred and only one (2%) of the SCCs recurred a few months postoperatively. These favourable cure rates using the modality of Mohs surgery are the reason for highlighting this technique in the current review. **Keywords** *skin cancer Mohs micrographic surgery facial plastic surgery*

Skin cancers are the most common malignancies occurring in the Caucasian population. Basal cell carcinoma (BCC) represents 75%¹ and squamous cell carcinoma (SCC) 20% of cutaneous malignancies.² The other 5%, including melanomas, are beyond the scope of this article. Over the last decade, a significant rise in the incidence of skin cancer has been noted.^{1,3,5} However, despite this rise in incidence, the mortality rates have decreased, attesting to the effectiveness of increased public awareness, including sun protection, as well as improved physician knowledge and enhanced, more accessible therapy.¹

There are several methods of therapy for skin cancers including radiotherapy, cryotherapy, curettage/electrodessication, conventional excision and Mohs micrographic surgery.

Radiotherapy, cryotherapy and curettage/electrodessication are modes of field therapy heavily reliant on visual assessment of margins and without pathological control of complete removal. Conventional excision is often followed by limited pathological checking of margins.⁶ The latter contrasts with Mohs micrographic surgery, which was developed by Frederick Mohs⁷ in the mid-1930s and is described in detail below. Mohs micrographic surgery aims to assess 100% of the peripheral and deep margins of the specimen, based on an unconventional histopathological technique.

Although it is well established that conventional treatment modalities generally result in high cure rates for small well circumscribed primary tumours with well-defined borders, a comprehensive review of relevant studies over four decades demonstrates that the highest overall cure rate for primary as well as recurrent skin cancers is achieved by Mohs micrographic surgery (Table 1).^{8,9} These favourable cure rates using the modality of Mohs surgery are supported by the author's 9 years of experience and are the reason for highlighting this technique in the current review.

Correspondence: H.D. Vuyk, Department of Otolaryngology & Facial Plastic Reconstructive Surgery, Ziekenhuis Gooi Noord, Rijksstraatweg 1, 1261 AN Blaricum, The Netherlands. *Fellow of the European Academy of Facial Plastic Surgery.

Table 1. Five year recurrence rate of primary and recurrent BCC (compilation of representative studies by Rowe *et al* (1989)⁹

Treatment modalities	BCC	
	Primary	Recurrent
Surgical excision	10%	17%
Curettage-electrodessication	8%	40%
Radiotherapy	9% →-M>	∴ 10%
Cryotherapy	8%	>13%
Mohs micrographic surgery	1%	6%

Determination of tumour margins

Before any type of treatment for skin cancer is considered, the margins of the tumour are visually assessed. Often the visual assessment may be straightforward in a small-defined, well circumscribed tumour, such as a nodular-type BCC. Infiltrating and morpheaform BCCs may present as flat, atrophic teleangiectatic plaques or scar-like patches with notably indistinct margins, which may grow unnoticed for years in some patients. Severe actinic skin damage may further obscure margins. As a result, in cases of BCC or SCC with indistinct margins, excision of tissue or the determination of the width and depth of the field to be treated with curative radiotherapy or cryotherapy is extremely unreliable.^{10,12}

Studies on treatment safety margins of skin cancer provide clinical, albeit vague, recommendations,¹³ ranging from 2 to 10 mm.^{14,17} These recommendations are based on the assumption that tumour outgrowth occurs symmetrically in all directions and for all types of cancer. Despite its importance, only a few studies provide research data on growth pattern (mainly concerning BCC) and the margins of 'normal' tissue that should be included in the treatment.^{18,22} Data from these studies were collected by examining subclinical extension using microscopic control of complete lateral and deep margins with (modified) Mohs techniques.^{17,22} These studies have substantiated that, in contrast to previous assumptions, an asymmetrical subclinical growth pattern with one or multiple extensions seems to characterize the majority of BCCs, including small primary BCCs.¹⁹ Thus, in order to perform radical excisions, conventional safety margins at the time of surgery are dictated by these specific extensions, while sacrificing a certain amount of non-involved tissue.

The magnitude of subclinical outgrowth in BCC is largely related to the histological type and size of the tumour. Suggestions regarding treatment margins can be made based on these specific characteristics. For example, a case of a small primary nodular BCC with a diameter of <10mm requires a 3 mm margin to include all tumour extensions in 80% of cases.^{19,21} Morpheaform or infiltrating-type BCCs are, however, notoriously deceptive and send out subclinical extensions of >7mm beyond clinically estimated borders.^{19,24}

Recurrent tumours need notably larger margins than primary tumours.¹⁹

Curettage may help to a degree to delineate tumour margins further,²⁵ especially in nodular BCCs that are more friable and present a soft feel on curettage compared with normal healthy tissue. However, in deep invasive tumours, morpheaform sclerotic BCCs or recurrent tumours, curettage is of limited benefit in determining margins. For the same reason, curettage combined with electrodesiccation has only been therapeutically successful in experienced hands for small, well-defined lesions.²⁶

Pathological examination

In order to establish a quality of care in Mohs micrographic surgery, the methods available to the pathologist to examine tumour margins should be understood by the clinician.⁶ Logically, the more complete the examination of the margin, the higher the correlation between presence and absence of tumour and the subsequent recurrence.²⁷ For practical purposes, vertical transections (transverse or longitudinal sections, quadrant sections or a combination) through representative areas of the specimen are most commonly used.^{6,28} However, vertical sampling of sections at 2-3 mm intervals through the specimen evaluate less than 5% of the true surgical margin.^{27,29} Failure to identify residual finger-like extensions between the sampled areas is one of the most important factors in local recurrence, despite the pathology report indicating clear margins.³⁰

Peripheral vertical sectioning techniques are often used to evaluate the epidermal margins. Ideally, 100% of the specimen including the deep margins is examined.^{7,8,31} Routine peripheral sectioning in the case of rectangular- or triangular-shaped excisions of eyelids, ears or lips does indeed control 100% of the margins, but in other tumour locations, Mohs surgery has been developed using oblique peripheral sections, encompassing the peripheral and deep margins, combined with tissue coding and mapping.

The key to Mohs surgery is the excision and control of complete peripheral and deep resection margins in one plane, allowing orientation, identification, mapping and re-excision of microscopic tumour extension. These extensions can be followed without sacrificing inappropriate amounts of normal tissue, while yielding high cure rates and maximum preservation of tissue.^{7,23,25,33,4}

Mohs technique

The visible tumour margins are outlined with ink before injecting local anaesthesia. For local anaesthesia, a combination of lidocaine 1% and adrenaline 1:100000 is used for short-term anaesthesia, while marcaine 0.5% and adrenaline 1:200 000 is used for a longer period of local anaesthesia. With

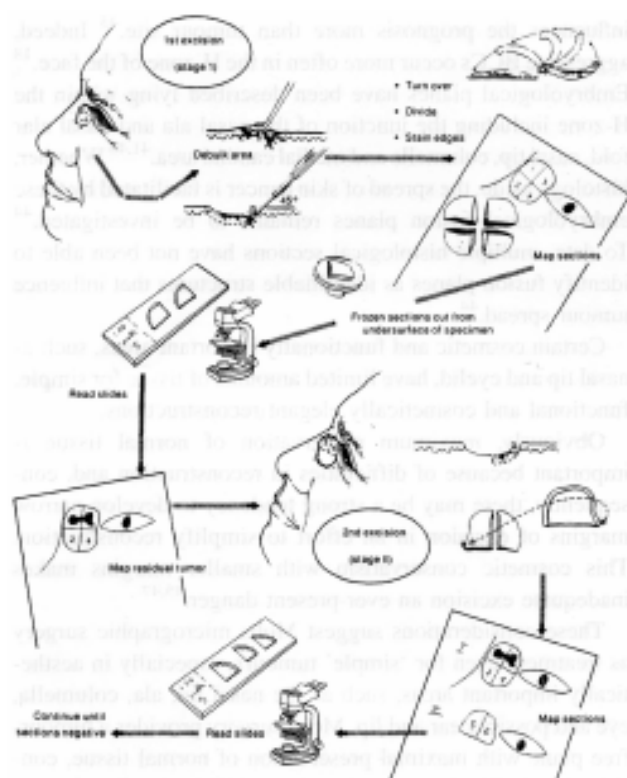


Figure 1. Schematic representation of Mohs micrographic surgery. After debulking the tumour, additional excision is performed using a bevelled knife. The peripheral and deep margins are colour coded and prepared for horizontal frozen sections. Using horizontal frozen sections 100% of the margins can be reviewed histologically. Mapping and colour coding help locate residual tumour mass. Only at sites in which tumour persists are additional slices of tissues excised, mapped, colour coded, prepared and subsequently histologically examined. This procedure is repeated until no tumour is found in the specimen, which leads to tumour-free wound edges.

curettage, soft, fragile cancerous tissue may be removed, further helping to identify the extent and depth of the tumour. Subsequently, the lesion is excised with approximately a 3 mm margin of macroscopically normal tissue. This additional surgical margin may be varied according to variables such as tumour type, previous treatments and the aesthetic importance of the area treated.

For Mohs micrographic surgery it is essential to obtain a flat, thin-layered tissue specimen (Fig. 1). Thus, the knife and incisions are bevelled at a 45° angle to the skin surface. Next, the deep surface is incised parallel to the skin surface. The removed specimen is orientated to the defect using ink, sutures, staples or hatchmarks. In the laboratory, the specimen is divided into sizes appropriate for frozen section processing³⁶ and colour coded. On a map delineating tumour site, shape of excised specimen and markings, the manner of division and colour coding is outlined prior to histological processing.

In order to produce sections that encompass the deep surface and the epidermal circumference of the specimen simultaneously, it is essential to obtain a horizontal surface of the tissue block that is subsequently mounted and cut in the cryostat. The deep portion of the specimen is transferred onto a glass slide. Full contact between the tissue and the glass interface is assured by gradual localized finger pressure while inspecting the slide from below. Subsequently, the compressed tissue is 'glued' to the glass slide using N₂ cryospray.³⁷

These manoeuvres, including bevelled excision, produce a flat undersurface with the epidermal margin and the inferior surface of the specimen exposed in a single plane for cutting with a microtome, and subsequent preparation for histological examination. A small amount of optimal cutting temperature-embedding compound is applied to the specimen and the glass slide with tissue is turned over so that the cut surface is facing upwards. This is then placed on a cryostat.

To optimize precise planar orientation of the undersurface of the specimen parallel to the cryostat chunk, a heat extractor is placed onto the glass slide containing the tissue until freezing of the specimen is complete. The slide is finally separated from the specimen by warming it with a finger and the undersurface of the specimen on the chunk is carefully orientated, parallel to the cryostat knife blades. This is essential, otherwise incomplete sections or deep complete sections cutting towards (and even into) the tumour may result.³⁸

A trained laboratory assistant then proceeds to cut horizontal slides of 15-micron thickness. The first complete section and then a number of deeper sections are placed on a microscopic slide and coloured using toluidine blue. Then, an experienced pathologist examines each slide under the microscope with the quality of the slides evaluated for the completeness of the sections, which should include a deep surface and an epithelial border. Suspicious sites or evidence of tumour are marked on the reference map and communicated to the surgeon. One Mohs cycle, excluding the excision itself, takes ~45 min.

The patient is taken to the operating room and additional local anaesthetic is injected if necessary. If further excisions are needed, the localization of any residual tumour or suspicious sites is facilitated with relative accuracy using the reference map placed beside the patient. The tissue is removed only at the sites indicated, with the rest of the defect left intact. The process is repeated until a tumour-free plane is obtained and adequate margins have been established. This surgical procedure, which includes a number of steps (Table 2), is meant to result in a defect reflecting the tumour's true extent with maximal preservation of normal tissue.³⁹

Indications for Mohs surgery

Mohs surgery may be specifically indicated for SCC and a subset of BCC. The subset of BCC includes BCC with

Table 2. Essentials for Mohs surgery

- Outline of macroscopic margins
- Optional curettage
- Bevelled incision
- Specimen orientation
- Mapping and colour coding
- Flattening of specimen
- Horizontal sectioning
- Staining
- Interpretation
- Communication

unfavourable histology, unfavourable location, incompletely removed BCC, recurrent BCC and large BCC. These indications follow guidelines developed by the American Academy of Dermatology.

UNFAVOURABLE HISTOLOGY

For the reasons mentioned above, aggressive BCCs with poorly defined clinical margins and deep tissue invasion (morpheaform, infiltrative-type, sclerosing and basosquamous BCC) have higher recurrent rates than well-defined nodular-type BCCs.^{24,40} These specific tumours represent a special therapeutic problem for which Mohs surgery may be the most appropriate form of treatment (Fig. 2).^{25,41}

UNFAVOURABLE LOCATION

Certain anatomical sites warrant the need for special consideration, with Mohs' surgery offering the best treatment solution.²⁵ The following areas are considered to be particularly difficult to treat: ears, periauricular region, temporal region, periocular region, nasal tip ala, melolabial sulcus and upper lip.^{23,42} These areas together constitute the so-called 'H-zone' of the face.²⁴

The exact significance of anatomical location is not clear, but it is probable that tumour histology and behaviour

influences the prognosis more than tumour site.⁴³ Indeed, aggressive BCCs occur more often in the H-zone of the face.¹⁸ Embryological planes have been described lying within the H-zone including the junction of the nasal ala and nasal alar fold, nasal tip, columella and medial canthal area.^{41,46} Whether, histology aside, the spread of skin cancer is facilitated by these embryological fusion planes remains to be investigated.⁴⁴ To date, multiple histological sections have not been able to identify fusion planes as identifiable structures that influence tumour spread.⁴⁴

Certain cosmetic and functionally important areas, such as nasal tip and eyelid, have limited amounts of tissue for simple, functional and cosmetically elegant reconstructions.

Obviously, maximum preservation of normal tissue is important because of difficulties in reconstruction and, consequently, there may be a strong tendency to develop narrow margins of excision in an effort to simplify reconstruction. This cosmetic conservatism with smaller margins makes inadequate excision an ever-present danger.^{45,47}

These considerations suggest Mohs micrographic surgery as treatment even for 'simple' tumours, especially in aesthetically important areas, such as the nasal tip, ala, columella, eye and possibly ear and lip. Mohs surgery provides a tumour-free plane with maximal preservation of normal tissue, considerably facilitating reconstruction, while improving chances of optimal function and cosmesis (Fig. 2).

INCOMPLETE TUMOUR REMOVAL

Previously, the need to re-excise a BCC with positive margins has been debated.⁹ There is no doubt that the presence of tumour at the specimen margin markedly increases the chances of recurrence independent of other variables, such as tumour histology, location and host response.¹¹ Approximately 40% of these BCCs with positive histological margins and no further therapy, will recur at 5 years follow-up.^{9,48} An additional 5% may reoccur even after the 5 year follow-up period.⁴⁹ The explanation for some of these residual tumours

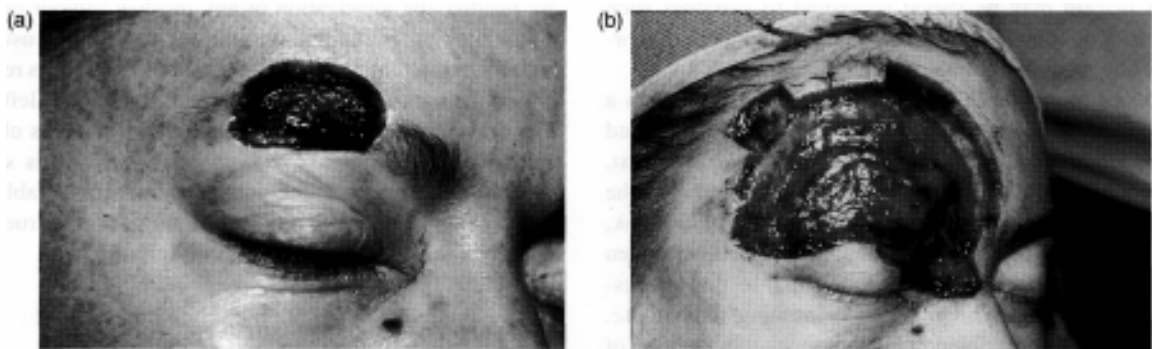


Figure 2. (a) Defect after first excision including a 3 mm margin of apparently healthy normal tissue (sclerosing BCC). Note apparent non-involved forehead skin around defect, (b) Final defect after seven stages of Mohs micrographic surgery.

remaining quiescent is possibly explained by inflammatory or immune responses directed to the residual tumour.⁵⁰ Alternatively, residual tumour may be trapped in scar tissue, remaining silent for years.⁵¹ The most rational approach to marginal involvement is re-excision^{15,52,53} and, in these situations, Mohs surgery may be used, permitting high cure rates and optimal tissue preservation.

RECURRENT TUMOUR

There are various reasons why recurrent tumours are more difficult to treat than primary tumours. These tumours may have an aggressive growth pattern.^{40,54} Indistinct margins associated with significant subclinical growth compound the therapeutic problem. Generally speaking, the cure rate of a given Standard modality is normally \sim 90%, but it drops to 50% if the same treatment modality of the primary tumour is applied to the recurrence.^{41,55} Even if other treatment regimens are chosen, the overall cure rates are generally unsatisfactory (Table 1).

Mohs surgery does not rely on difficult estimates of three-dimensional histology (lateral extensions and depth) of recurrent tumours, but provides optimal marginal control with 5-year cure rates in excess of 90%.^{56,58} It should be noted that, even with Mohs surgery, the entire scar including flap or graft, as well as a deep margin of original resection, should be re-excised because tumour tends to move in previously dissected planes and possible nests of discontinuous tumour may present after previous treatment.⁵¹

LARGE TUMOUR SIZE

The greater the diameter of a lesion, the greater the likelihood of recurrence.^{26,57,58} For example, BCCs <6 mm on the head have higher cure rates with conventional excision than larger lesions.⁵⁸ What is considered large depends somewhat on the anatomical location. A 1-cm lesion on the forehead may be considered small, while the same size lesion in the medial canthus may be considered large. Even Mohs surgery, although more effective than other treatment modalities, has a high recurrence rate when the lesions are >2-3cm.^{10,59} For SCCs larger than 2 cm, the recurrence rate doubles and the metastatic rate triples compared with lesions <2cm.² Given the possibility of human error, patients at high risk for recurrence can be managed with wider clear tissue margins taken at the time of surgery to increase the chance of complete tumour removal. For Mohs surgery, this involves an extra tumour-free stage of tissue, which might be performed after the usual completion of surgery in these patients.⁵⁷

Because of the relatively high recurrence rates for large and deeply invasive tumours, it is sometimes prudent to delay permanent reconstruction for 1-2 years, using skin grafts and prostheses in the interim.¹⁰ In BCCs, the size of the primary

lesion may play a role in the metastatic potential, which is generally very low. In BCCs > 1 cm or present for more than 2 years, behaviour may become more unpredictable.⁹

SQUAMOUS CELL CARCINOMA

Compared with BCC, SCC is a more aggressive tumour with potential for distant metastases and death.²⁰ The clinical factors that correlate with a high risk of local recurrence and with metastases include size, depth, histological differentiation, site, scar carcinoma, histological evidence of perineural involvement, previous treatment and immunosuppression.^{32,60} Most SCCs in high-risk locations, such as scalp, ears, eyelid, nose and lips, need at least a 6 mm margin for excision.²⁰ It is recommended that excision of all SCCs should include subcutaneous fat, because at least 30% invade to this level.²⁰

Complete SCC removal is essential, as recurrent tumours are more difficult to eradicate and are associated with a 25-45% rate of metastasis.⁶¹ Cutaneous micrographic surgery remains the surgical method with the highest cure rate for localized SCC (97%).³² Mohs surgery offers the highest cure rates, even for SCC with perineural invasion.^{13,62,64} However, more aggressive therapy, e.g. the employment of larger surgical margins or additional stages of Mohs surgery beyond the tumour-free planes, may be necessary to decrease the risk of local recurrence.^{13,63,65} It should be emphasized that in cases of perineural invasion in which an additional inflammatory response is observed around a nerve branch, the nerve should be traced microscopically until the perineural reaction is no longer observed.^{65,66} Any patient with SCC has a higher potential for regional metastasis and should be managed by a multidisciplinary team.⁶⁷ For example, patients with SCC and perineural invasion may possibly benefit from postoperative radiotherapy.⁶⁸ Delay of ultimate reconstructive surgery after Mohs surgery in certain patients may also be prudent to ensure that there is no recurrence under flaps or grafts.⁶³

Results of own experience with Mohs surgery

During an 8-year study period, 369 BCCs and 56 SCCs of the head and neck were treated in our department using Mohs surgery (Table 3). The most common sites of treatment were the nose (54%) and the ear (18%) (Table 4). The patients consisted of 227 men and 198 women. Age ranged from 23 years to 95 years with a mean of 72 years. Of the BCCs, 223 (60%) were identified as solid, 135 (37%) as sclerosing and 11 (3%) as superficial. Of these, primary lesions numbered 326 (88% of total BCCs) and recurrent lesions 43 (12% of total BCCs). It appeared that 19% of the sclerosing BCCs, 9% of the superficial BCCs and 8% of the solid BCCs were recurrent lesions, indicating the sclerosing type to be more aggressive. Of the total number of 56 SCCs treated with Mohs,

Table 3. Type of non-melanoma facial skin cancer treated using Mohs surgery

	Primary	Recurrence	Total
BCC			
Solid	206	17	223
Sclerosing	110	25	135
Superficial	10	1	11
sec*	53	3	56
Total	379	46	425

*SCC ranging from well to poorly differentiated.

Table 4. Localization of non-melanoma facial skin cancers treated using Mohs surgery

n	%
Nose	230
Ear	78
Lip/chin	imh -jjigföin
Forehead/temple/scalp	33
Eye	28
Cheek	12
Neck	2
Total	425

three (5%) were recurrent lesions. The SCCs ranged from poorly to well differentiated.

With a mean follow-up of 33 months, ranging from 3 months to 99 months, only one of the Mohs-treated lesions (0.002%) recurred. It was an SCC of the tragus of the ear, which demonstrated signs of perineural invasion around the facial nerve a few months postoperatively. All the other Mohs surgery-treated tumours have been free of local recurrence to date.

Discussion

LIMITATIONS OF MOHS SURGERY

A number of factors may limit the albeit high cure rate of Mohs surgery, the most important being discontinuous tumour growth and technical flaws.^{69,70}

The major premise of Mohs surgery is based on continuous tumour growth.^{60,70} Tumours presenting in a discontinuous fashion (e.g., in Paget's extra mammary disease) are less treatable because breaks in tumour continuity may be as a result of the production of intervening scar tissue by multiple treatments (iatrogenically induced multifocality).^{51,71} If satel-lite islands of tumour exist mat are separate from the main tumour mass, histopathological examination of margins by any method will be inadequate in demonstrating residual neoplasm.^{63,72} For these reasons, Mohs surgery (as well as

conventional surgery) should include the entire region of previous treatment and not only treat the clinical recurrence in order to improve cure rates.^{23,42,52,60}

Scrupulous attention to technical detail helps to prevent technical flaws in the Mohs surgical procedure aimed at reducing the potential for false negative margins (Table 2).⁶⁰ Indeed, suboptimal pathological slices have been shown to be a major factor in most failures. Technically, the most difficult part of the Mohs procedure is the production of a horizontal frozen section that includes all the epidermal edges through to the true depth of the specimen, providing a complete sample of margins. As discussed earlier, tumour excision at 45° is the first step to facilitate forcing the epidermis into the same plane as the deep tissue.³⁵ Thicker tissue specimens are more difficult to compress and partial scoring incisions may help to compress all margins flat onto the glass slide, using finger pressure on the specimen with visual control through the glass slide. Large tissue surfaces are more difficult to orientate parallel to the cryostat knife, risking squeezed, incomplete sections. Despite numerous techniques, devices and meticu-lous effort, it is probably impossible to view 100% of the epidermal and deep margins.^{71,73}

The quality of frozen sections may also be suboptimal for various other reasons.⁶ Adipose tissue is notoriously difficult to cut with the cryostat.⁵⁹ Paraffin-embedded sections may thus be useful in this scenario.^{74,76}

Thin specimens may fragment producing holes or folds in the cutting process. Deeper sections reduce this problem, but risk moving away from the true margin and cutting into the tumour, producing false positive margins. Slide interpretation may be difficult as pathologists are not usually accustomed to viewing horizontal skin sections. For example, longitudinal sections of hair follicles, sweat glands or blood samples may resemble BCC.^{71,77}

Human errors may occur during the many steps for orientation, mapping, incising, freezing and interpreting frozen sections.^{78,79} If the surgeon himself does not interpret the frozen sections, communication with the pathologist and laboratory technician becomes extremely important.⁸⁰ In our setting, the surgeon performs the whole surgical procedure including excision and supervision of mounting of sections by the technician, leaving the interpretation to the pathologist. Dis-orientation of positive margins may result in further excision of healthy tissue (instead of remaining tumour), yielding false negative margin reports.

While aiming to produce optimal cure with maximal tissue conservation, Mohs surgery may at times produce excessively wide margins. If the technician fails to provide a complete section at the earliest possible moment, he may cut too deeply into the tissue block and even into the tumour. A false positive margin will consequently lead to further tissue sacrifice.⁷⁴

Although unusual, total tumour eradication may be impos-sible with Mohs surgery in the case of large neglected tumours

that involve vital structures. These rare situations may not be amenable to any curative treatment.

THE COST/BENEFIT RATIO OF MOHS SURGERY

For small primary tumours with minimal chance of recurrence, routine procedures are efficient and very cost effective. Mohs surgery involves more expenses related to longer operating time and additional laboratory assistance. When performed in collaboration with a pathology department, specific equipment such as cryostat and microscopes are already available. As Mohs surgery greatly reduces the likelihood of recurrence in the future and allows closure during the same session, it is cost effective particularly in the treatment of recurrent tumours or primary tumours with a high incidence of recurrence following Standard treatment.^{13,78,81,83} Approximately 5% of Mohs surgeons believe that all BCCs require Mohs surgery,⁸⁴ but most will agree that mis is excessive use of resources, despite the extremely high cure rates.⁷⁶

Conclusion

Of all the modalities for treating skin cancer, Mohs surgery has the highest cure rate, made possible by its accurate histological margin evaluation. Theoretically, the method evaluates nearly 100% of tumour margins, in contrast to random margin evaluations performed routinely in most laboratories.

For the difficult situation, such as recurrent tumours, large tumours, tumours with aggressive behaviour, incompletely excised tumours and tumours in high-risk, aesthetically important anatomical areas, the value of Mohs surgery is well established. As a result of the success of Mohs surgery, most defects will be reconstructed primarily, although reconstruction method and timing should still be individualized to patients with high-risk tumours.

References

- GLOSTER A.M. & BRODLAND J.G. (1996) The epidemiology of skin cancer. *Dermatol. Surg.* 22, 217-226
- BERNSTEIN S.C., LIM K.K., BROTLAND D.G. *et al* (1996) The many faces of squamous cell carcinoma. *J. Dermatol. Surg.* 22, 243-254
- COEBERGH J.W.W., NEUMANN H.A.M., VRINTS L.W. *et al.* (1991) Trends in the incidence of non-melanoma skin cancer in the Netherlands 1975-88: a registry-based study. *Br. J. Dermatol.* 125, 353-359
- DAHL E., ABERG M., RAUSING A. *et al.* (1992) Basal cell carcinoma. *Cancer* 1(1), 104-108
- RIGEL D.S., FRIEDMAN R.J. & KOPF A.W. (1996) Lifetime risk for development of skin cancer in the U.S. population: Current estimate is now 1 in 5. *J. Amer. Acad. Dermatol.* 35 (6), 1012-1013
- RAPINI R.P. (1990) Comparison of methods for checking surgical margins. *J. Amer. Acad. Dermatol.* 23 (2), 288-294
- MOHS F.E. (1941) Chemosurgery, a microscopically controlled method of cancer excision. *Arch. Surg.* 42, 279-295
- ROWE D.E., CARROLL R.J. & DAY C.L. (1989) Long-term recurrence rate in previously untreated (primary) basal cell carcinoma. Implications for patient follow-up. *J. Dermatol. Surg. Oncol.* 15 (3), 315-328
- ROWE D.E., CARROLL R.J. & DAY C.L. (1989) Mohs surgery is the treatment of choice for recurrent (previously treated) basal cell carcinoma. *J. Dermatol. Surg. Oncol.* 15 (4), 424-431
- HRUZA G.J. (1990) Mohs micrographic surgery. *Otolaryngol. Clin. North Am.* 23, 845-864
- RITALA A. (1971) Surgical therapy of basal cell carcinoma: correlation of microscopic and macroscopic control of excision with recurrence. *Scand. J. Plast. Reconstr. Surg.* 5, 87-96
- RAKOFSKY S.I. (1973) The adequacy of the surgical excision of basal cell. *Annals Ophthalmol.* 5, 596-600
- SHRINER D.L., MCCOY D.K., GOLBERG DJ. *et al.* (1998) Mohs micrographic surgery. *J. Amer. Acad. Dermatol.* 39, 79-97
- EPSTEIN A. (1973) How accurate is the visual assessment of basal cell carcinoma margins? *Br. J. Dermatol.* 89, 37-42
- KOPLIN L. & ZAREM H.A. (1980) Recurrent basal cell carcinoma. A review concerning the incidence, behaviour and management of recurrent basal cell carcinoma, with emphasis on the incompletely excised lesion. *Plast. Reconstr. Surg.* 65 (5), 656-664
- GRIFFITH B.H. & MCKINNY P. (1973) An appraisal of treatment of basal cell carcinoma of the skin. *Plast. Reconstr. Surg.* 51, * 565-571
- VERHAEGH M.E.J.M., GRUINTEIJS F.W.G., KRENELS G.A.M. *et al.* (1998) Surgical margins for excision of primary and recurrent basal cell carcinoma. pp. 93-106. In *Growth Characteristics of Basal Cell Carcinoma*. Thesis, University of Maastricht, Belgium
- BREUNINGER H., FLAD W. & RASSNER G. (1989) Investigations on the infiltration depth of basal cell carcinoma. *Zeitschr. Hautkrankh.* 64, 191-196
- BREUNINGER H. & DIETZ K. (1991) Prediction of subclinical tumour infiltration in basal cell carcinoma. *J. Dermatol. Surg. Oncol.* 17, 574-578
- BRODLAND D.G. & ZITELLI J.A. (1992) Surgical margins for excision of primary cutaneous squamous cell carcinoma. *J. Amer. Acad. Dermatol.* 27, 241-248
- WOLFF DJ. & ZITELLI J. A. (1987) Surgical margins of basal cell carcinoma. *Arch. Dermatol.* 123, 340-344
- BURG G., HIRSCH R.D., KONZ B. *et al.* (1975) Histographic surgery: accuracy of visual assessment of margins of basal cell epithelioma. *J. Dermatol. Surg.* 1 (3), 21-24
- BUMSTED R.M. & CEILLEY R.I. (1982) Auricular malignant neoplasms. Identification of high-risk lesions and selection of method of reconstruction. *Arch. Otolaryngol.* 108, 225-231
- SALACHE S.J. & AMONETT R.A. (1981) Morpheiform basal cell epitheliomas. A study of subclinical extension in a series of 51 cases. *J. Dermatol. Surg. Oncol.* 56, 387-394
- SWANSON N.A., GREKIN R.C. & BAKER S.R. (1983) Mohs surgery: techniques, indications, and applications in head and neck surgery. *Head & Neck Surg.* 80, 683-692
- SILVERMAN M., KOPF A., BART R. *et al.* (1991) Recurrence rates of treated basal cell carcinomas. Part II: Curettage-electrodesiccation. *J. Dermatol. Surg. Oncol.* 17, 720-726
- ABIDE J.M., NAHAI F. & BENNETT R.G. (1984) The meaning of surgical margins. *Plast. Reconstr. Surg.* 73, 492-496
- FREEMAN R.G. (1982) The handling of pathologic specimens for gross and microscopic examination in dermatologic surgery. *J. Dermatol. Surg. Oncol.* 8, 673-679
- DAVIDSON T.M., NAHUM A.M. & HAGHIGHI P. (1984) Biology of head and neck cancer. *Arch. Otolaryngol.* 110, 193-196

- 30 SNOW S.N. (1991) Techniques and indications for Mohs micrographic surgery. In *Mohs Micrographic Surgery*, pp 11-60. Saunders Company, Philadelphia
- 31 BREUNINGER H. (1984) Histologic control of excised tissue edges in the operative treatment of basal cell carcinoma. *J. Dermatol Surg. Oncol.* 9, 724-728
- 32 ROWE D.E., CARROLL R.J. & DAY C.L. (1992) Prognostic factors for local recurrence, metastasis and survival rates in squamous cell carcinoma of the skin, ear and lip. *Amer. Acad. Dermatol.* 6, 976-990
- 33 MIKHAIL G.R. (1991) *Mohs Micrographic Surgery*. W.B. Saunders, Philadelphia
- 34 NEUMANN H.A.M., KREKELS G.A.M. & VERHAEGH M.E.J.M. (1996) Treatment of 208 extensive basal cell carcinoma with Mohs micrographic surgery. *J. Europ. Acad. Dermatol. Venerol.* 6, 217-225
- 35 TROMOWITZ D.A. & STEGMAN S.J. (1974) Microscopically controlled excision of skin tumours. Chemosurgery (Mohs): fresh tissue technique. *Arch. Dermatol.* 110, 231-232
- 36 PICOTO A.M. & PICOTO A. (1986) Technical procedures for Mohs fresh tissue surgery. *J. Dermatol. Surg. Oncol.* 12, 134-138
- 37 SNOW S.N. & LANDECK A.E. (1998) Practical Aspects of Mohs Surgery. *Fac. Plast. Surg. Clin. North Am.* 6, 251-266
- 38 RANDLE H.W., ZITELI J., BRODLAND D.G. *et al* (1993) Histologic preparation of Mohs micrographic surgery. A single sectioning method. *J. Dermat. Surg. Oncol.* 19, 522-524
- 39 FEWKES J.L., CHENEY M.C. & POLLACK S. (1992). *Illustrated Atlas of Cutaneous Surgery*. Lippincott, Philadelphia
- 40 LEVINE H.L. & BAILIN P.L. (1980) Basal cell carcinoma of the head and neck. Identification of a high-risk patient. *Laryngo-scope* 60, 955-961
- 41 STEGMAN S.J. (1986) Basal cell carcinoma and squamous cell carcinoma. Recognition and treatment. *Med. Clin. North Am.* 70 (1), 95-107
- 42 MORA R.G. & ROBINS R. (1978) Basal cell carcinoma in the centre of the face: special diagnostic, prognostic and therapeutic considerations. *J. Dermatol. Surg. Oncol.* 4, 315-321
- 43 TEICHGRABER J.F. & GOEPFERT H. (1990) Rhinectomy, timing and treatment. *Otolaryngol. Head & Neck Surg.* 102,361 -369
- 44 WENTZEL J.L. & ROBINSON J.K. (1996) Embryologic fusion planes in the spread of cutaneous carcinoma: a review and reassessment. *J. Dermatol. Surg. Oncol.* 16 (11), 1000-1006
- 45 ROBINS P. & ALBOM M.J. (1975) Recurrent basal cell carcinoma in young women. *J. Dermatol. Surg.* 1, 49-51
- 46 PANJE W.R. & CHEILLEY R.I. (1979) The influence of embryology of the midface on spread of epithelial malignancies. *Laryngoscope* 89, 1914-20
- 47 LAURITZEN R.E., JOHNSON R.E. & SPRATT J.S. (1965) Pattern of recurrence in basal cell carcinoma. *Surgery* 57, 813-816
- 48 DELLON A., DE SILVA S., CONNOLLY M. *et al.* (1985) Prediction of recurrent completely excised basal cell carcinoma. *Plast. Reconstr. Surg.* 75, 860-871
- 49 PASCAL R.R., HOBBY L.W., LATTES R. *et al.* (1968) Prognosis of an 'incompletely excised' versus 'completely excised' basal cell carcinoma. *Plast. Reconstr. Surg.* 41, 328-332
- 50 DIXON A.Y., LEE S.H. & MCGREGOR D.A. (1989) Factors predictive of recurrence of basal cell carcinoma. *Amer. J. Dermatopathol.* 11 (3), 222-232
- 51 WAGNER R.F. & COTTEL W.I. (1987) Multifocal recurrent basal cell carcinoma following primary tumour treatment by electrodesiccation and curettage. *J. Amer. Acad. Dermatol.* 17, 1047-1049
- 52 CASSON, P. (1980) Basal cell carcinoma. *Clin. Plast. Surg.* 7, 301-11
- 53 VERHAEGH M.E.J.M. (1998) Growth characteristics of basal cell carcinoma. Thesis, University of Maastricht, Belgium
- 54 SMITH S.P., FOLEY E.H. & GRANDE DJ. (1990) Use of Mohs micrographic surgery to establish quantitative proof of heightened tumour spread in basal cell carcinoma carcinoma recurrent following radiotherapy. *J. Dermatol. Surg. Oncol.* 16, 1012-1016
- 55 MENN H., ROBINS B., KOPF A.W. *et al.* (1971) The recurrent basal cell epithelioma. A study of 100 cases of recurrent, re-treated basal cell epitheliomas. *Arch. Dermatol.* 103, 628-631
- 56 BAARTWIJK A.A.W., VERHAEGH M.E.J.M., KREKELS G.A.M. *et al.* (1997) Micrographic surgery according to Mohs as treatment for recurrent basal cell carcinoma. *Dutch Med. J.* 141, 524-529
- 57 RIGEL D.S., ROBINS P. & FRIEDMAN R.J. (1981) Predicting recurrence of basal cell carcinomas treated by microscopically controlled excision. *J. Dermatol. Surg. Oncol.* 9, 807-810
- 58 SILVERMAN M., KOPF A., BART R. *et al* (1992) Recurrence rates of treated basal cell carcinoma, part III: Surgical excision. *J. Dermatol. Surg. Oncol.* 18, 474 476
- 59 MOHS F.E. (1978) *Keynote Surgery: Microscopically Controlled Surgery of Skin Cancer*. C.C. Thomas, Springfield, IL
- 60 CLARK D. (1993) Cutaneous micrographic surgery. *Otolaryngol. Clin. North Amer.* 26 (2), 185-202
- 61 TAYLOR G. & BARISONI D. (1973) Ten years experience in the surgical treatment of basal cell carcinoma: a study of factors associated with recurrences. *Br. J. Surg.* 60, 522-525
- 62 LAWRENCE N. & COTTEL W.I. (1998) SCC with perineural invasion. *Fac. Plas. Surg. Clin. North. Amer.* 6, 297-307
- 63 DZUBOW L.M., RIGEL D.S. & ROBINS P. (1982) Risk factors for local recurrence of primary cutaneous SCC. Treatment by microscopically controlled excision. *Arch. Dermatol.* 118, 900-902
- 64 ROBINS P, DZUBOW L.M. & RIGEL D.S. (1981) Squamous cell carcinoma treated by Mohs surgery: an experience with 414 cases in a period of 15 years. *J. Dermatol. Surg. Oncol.* 9, 800-801
- 65 AMPIL F.L., HARDON J.C., PESKIND S.P. *et al.* (1995) Perineural invasion in skin cancer of the head and neck: a review of nine cases. *J. Oral Maxillofac Surg.* 53, 34-38
- 66 MATORIN P.A. & WAGNER R.F. (1992) Mohs micrographic surgery: Technical difficulties posed by perineural invasion. *Int. J. Dermatol.* 31, 83-86
- 67 COOK J.L. & DZUBOW L.M. (1998) The multidisciplinary approach to the management of advanced non-melanoma skin cancer. *Fac. Plast. Surg. Clin. North Am.* 6, 387-401
- 68 BARRETT T.L., GREENWAY H.T., MASULLO V. *et al.* (1993) Treatment of basal cell carcinoma and squamous cell carcinoma with perineural invasion. *Adv. Dermatol.* 8, 277-305
- 69 HRUZA G.J. (1994) Mohs micrographic surgery local recurrences. *J. Dermatol. Surg. Oncol.* 20, 573-577
- 70 HRUZA G.J. (1998) Limitations and recurrences with the Mohs technique. *Fac. Plast. Surg. Clin. North Am.* 6, 347-363
- 71 DZUBOW L.M. (1987) Chemosurgical report: recurrence (persistence) of tumour, following excision by Mohs surgery. *J. Dermatol. Surg. Oncol.* 13, 27-30
- 72 SEIDMAN. J.D., BERMAN J.J. & MOORE G.W. (1991) Basal cell carcinoma: the importance of histologic discontinuities in the evaluation of resection margins. In *Modern Pathology*, pp 325-330
- 73 HANKE C.W. & LEE M.W. (1989) Mohs surgery report. *J. Dermatol. Surg. Oncol.* 15, 29-32
- 74 RAPINI R.P. (1990) Pitfalls of Mohs micrographic surgery. *J. Amer. Acad. Dermatol.* 22, 681-686
- 75 SNOW S.N. (1991) Technique and educations for Mohs micrographic surgery. In *Mohs Micrographagic Surgery*, pp 11-60. Saunders, New York

- 76 RAPINI R.P. (1999) Pitfalls and abuses of Mohs surgery. In: *Mohs Surgery, Fundamentals and Techniques*, chapter 20. Mosby, St Louis
- 77 COCKERELL C.J. (1985) Mohs surgery. Let's make a good thing better. *Amer. J. Dermatol. Pathol.* 7, 587-588
- 78 ZITELLI J.A. (1985) Mohs surgery. Concepts and misconceptions. *Intern. J. Dermatol.* 24, 544-548
- 79 GRABSKI W.J. & SALASCHE S.J. (1991) Mapping and orienting tissue during Mohs micrographic surgery. An alternate approach. *J. Dermat. Surg. Oncol.* 17, 865-868
- 80 COTTEL W.I., BAILIN B.L., ALBOM M.J., *et al* (1988) Essentials of Mohs micrographic surgery. *J. Dermatol. Surg. Oncol.* 14, 11-13
- 81 MILLER P.K., ROENIGK R.K., BRODLAND D.G. *et al.* (1992) Cutaneous micrographic surgery: Mohs procedure. *Mayo Clin. Proc.* 67, 971-980
- 82 BERNSTEIN P.E. (1999) Mohs '98: Single procedure Mohs surgery with immediate reconstruction. *Otolaryngol. Head & Neck Surg.* 120 (2), 184-189
- 83 COOK J. & ZITELLI J.A. (1998). Mohs micrographic surgery versus vertical excision with frozen section: a cost analysis. *Dermatol. Surg.* 24, 492-483
- 84 MCGILLIS S.T., WHEELAND R.G. & SEBBEN J.E. (1991) Current issues in the performance of Mohs micrographic surgery. *J. Dermatol. Surg. Oncol.* 17, 681-684

t

t? !f» f til & ?\n n ^ tii M

© 2001 Blackwell Science Ltd, *Clinical Otolaryngology*, 26, 265-273