

# Nasal dorsal cyst after rhinoplasty<sup>^</sup>

T. D. Zijlker<sup>1</sup>, H. D. Vuyk<sup>2</sup>

<sup>1</sup> Department of Otorhinolaryngology and Head & Neck Surgery, University Hospital, Maastricht, The Netherlands

<sup>2</sup> Department of Otorhinolaryngology and Facial Plastic Surgery, Gooi-Noord Hospital, Blaricum, The Netherlands

## SUMMARY

*Nasal dorsal cystformation after rhinoplasty is considered a rare complication. These cysts are due to entrapment of mucosal remnants in the subcutaneous space. Meticulous surgical technique aimed at preserving the mucosal lining may prevent cyst formation. Surgical excision with the open approach is a reliable treatment. A case of nasal dorsal cyst after previous rhinoplasty is presented. After four years no sign of recurrence is noted,*

*Key words: nasal dorsal cyst, open rhinoplasty*

## INTRODUCTION

Rhinoplasty is considered a major challenge in facial plastic and reconstructive surgery. In fact, the nose is the most prominent part of the face. Moreover, failures are difficult to correct and may put the surgeon's reputation at stake. Late complications of rhinoplasty are not common, but may be serious and difficult to manage. Nasal dorsal cyst formation is such a rare complication. Only several case reports have been presented in the literature (McGregor et al., 1958; Mouly, 1970; Anderson et al., 1982; Lawson et al., 1983; Suhlman and Westreich, 1983; Johnson and Toriumi, 1990).

This case report adds one more patient with a nasal dorsal cyst to the previous reported cases. The possible etiology, prevention and management of this rare condition following rhinoplasty will be discussed.

## CASE REPORT

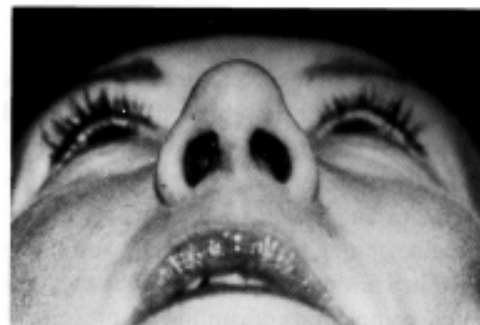
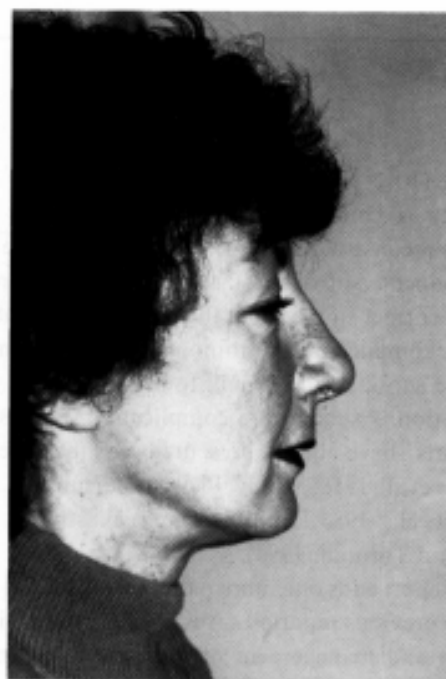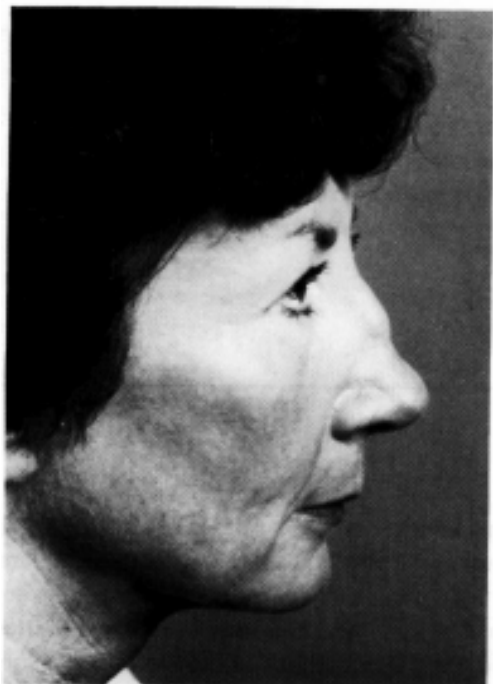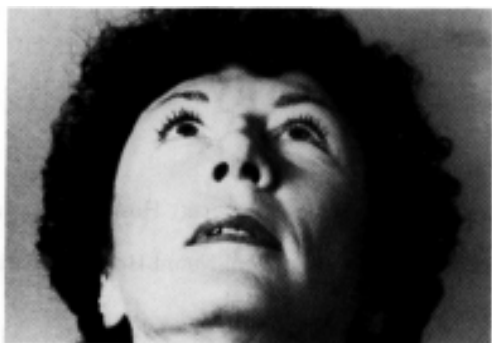In 1978, a 31-year-old female underwent a septal correction, five years after her first rhinoplasty. In 1979 she was surgically treated because of an apparent dorsal swelling, present for already several years. In an attempt to remove the swelling, using an endonasal approach, the cyst ruptured at the beginning of the procedure, and the swelling re-occurred in a few months' time. In 1988 she was seen at our hospital, complaining of continuous pressure over the nasal dorsum and an unaesthetic appearance of her nose. On inspection (Figures IA and B) the swelling was obvious. The nasal tip was relatively overprojecting, in consideration of the very low bony and cartilaginous

dorsum, which has been over-resected previously. The skin over the lesion was extremely thin, with some teleangiectasis.

An open rhinoplasty was carried out in an attempt to remove the lesion radically and to reconstruct the dorsal profile. The swelling could be removed *in toto*. The large dorsal defect caused by previous over-aggressive surgery was reconstructed with homologous cartilage. As some resorption of the graft is to be anticipated over the years a slight over-correction was carried out. The nasal tip was set back by reducing the length of the lateral crus of the alar cartilages at the hinge area with concomitant reduction of the medial crural height at both sides. After a two-year follow-up our patient is free of complaints and no sign of a recurrence is seen (Figures 2A-C).

## AETIOLOGY

Most nasal cysts are attributed to entrapment of nasal mucosal remnants in the subcutaneous space. An entrapped mucosal remnant can be considered a free graft and is assumed to develop a cyst. Entrapment of epithelium from the nasal vestibule or mucosal lining may be caused by transcutaneous osteotomies. In our patient, the high bony and cartilaginous dorsum had been excessively reduced during the first operation. The cyst is probably caused by free mucosal remnants, as there was no connection with the internal nasal lining. One may conclude that retention cysts are likely to occur once the intranasal mucosal lining is violated and mucosal remnants become displaced, when allowed to remain subcutaneously.



Figures 1A-B. Nasal dorsal cyst obvious in our pre-operative photographs. The cartilaginous and bony dorsum are extremely low, with relatively overprojected nasal tip.

PREVENTION

In order to prevent iatrogenic cyst formation it is important to keep the mucosal lining intact during the subsequent rhinoplasty manoeuvres, or to meticulously restore the disturbed mucosal lining. Mucosal lining can be preserved when subperichondrial and subperiosteal tunnels are being established over the septum and under the nasal dorsum before any surgical alterations be made to these structures.

MANAGEMENT

Complete surgical extirpation of the lesion, with reconstruction of the resulting defect, sets the goals of surgical treatment of this rare condition. Satisfactory exposure of the area is critical in this respect. Exposure can be obtained by using traditional endonasal or external transcolumellar incisions (Berendes, 1962; Anderson et al., 1982; Adamson, 1987; Zijlker and Vuijk, 1990). Direct exposure with incisions in the dorsal skin over the cyst is a third option to be considered. The endonasal approach using inter- or intracartilaginous incisions offers limited exposure. The

Figures 2A-C. Post-operative result after eighteen months follow-up. The cyst is removed *in toto*, the dorsal defect reconstructed with homologous cartilage. Some overcorrection performed in view of a possible slight resorption in the future.

### *Nasal dorsol cvst*

external rhinoplasty approach using bilateral rim and transcolumellar incisions is recommended as it offers excellent exposure greatly facilitating complete extirpation of the lesion and reconstruction of the defect with an unobtrusive scar in the long run. In contrast, direct dorsal approach, even when a geometrically broken line incision is used, does preclude direct reconstruction of the defect and may well result in a visible scar on the nasal dorsum.

#### REFERENCES

1. Adamson PA (1987) Open rhinoplasty. *Otolaryngol Clin N Am* 20: 837-852.
2. Anderson JR, Johnson Jr CM, Adamson PA (1982) Open rhinoplasty: An assessment. *Otolaryngol Head Neck Surg* 90: 272-274.
3. Berendes J (1962) Kosmetisch schonendes Operationsverfahren bei angeborener Fistel des Nasenrucken. *Verhandlungen Deutschen Gesellschaft der Hals-Nasen-Ohrenarzte*. Springer-Verlag, Stuttgart, pp. 784-785.
4. English GM (1979) Dermoid cyst or teratoma of the head and neck. In: D Bergsma (Ed.) *Birth Defects Atlas and Compendium*, 2nd Edition. Williams & Wilkins, Baltimore, pp. 768-769.
5. Johnson CM, Toriumi DM (1990) *Open Structure Rhinoplasty*. WB Saunders, Philadelphia, pp. 464-467.
6. Lawson W, Kessler S, Biller H (1983) Unusual and fatal complications of rhinoplasty. *Arch Otolaryngol Head Neck Surg* 109: 164-169.
7. McGregor MW, O'Connor GB, Saffier S (1958) Complications of rhinoplasty. *J Int Coll Surg* 30: 179-184.
8. Mouly, R (1970) Le cyste mucoide. Complication inhabituelle de la rhinoplastie *Ann Chir Plast* 2: 153-155.
9. Suhlman Y, Westreich M (1983) Post-rhinoplasty mucous cyst of the nose. *Plast Recon Surg*: 421-422.
10. Zijlker TD, Vuyk HD (1990) De open septorinoplastiek; Ervaringen bij 80 patiënten. *Ned Tijdschr Geneesk* 134: 1303-1308.

T. D. Zijlker, MD  
Department of Otorhinolaryngology  
and Head & Neck Surgery  
University Hospital Maastricht  
P.O. Box 5800  
NL-6202 AZ Maastricht  
The Netherlands