

Suture tip plasty*

H.D. Vuyk

Department of Otolaryngology/Head and Neck Surgery, Gooi Noord Hospital, Blaricum, The Netherlands

SUMMARY

The three main characteristics of the nasal tip are projection, rotation, and contour. During rhinoplasty the surgeon will strive to preserve or change these characteristics in a predictable fashion, avoiding undesirable sequelae, even after long-term follow-up. Conservation, relocation and augmentation rather than reduction are key principles in modern rhinoplasty, i. e. for obtaining gratifying tip surgery. Interdomal suture, transdomal suture, and lateral crural steal follow these modern principles, while having their clear indications for different nasal tip pathology. All three types of techniques involve (semi-)permanent sutures to change the shape of alar cartilages and can be considered complementary. Based on the same surgical philosophy these three techniques can be captured with the term "suture tip plasty". The objective of this paper is to describe, in a retrospective fashion, a series of 112 patients in whom suture tip plasty has been used as part of the rhinoplasty procedure. The technique proved versatile with predictable results and few manageable complications.

Key words: nasal tip surgery, rhinoplasty, suture tip plasty

INTRODUCTION

Already in the beginning of this century, Fomon has stated: "He who masters the tip, masters rhinoplasty." This statement is still valid today and underlines the importance of control over nasal tip contour, projection and rotation during rhinoplasty. However, earlier rhinoplasty had a more aggressive nature with emphasis on reduction. Aggressive reduction may set the stage for unpredictable long-term healing and undesirable sequelae (Zylker and Vuyk, 1993). For this reason, rhinoplasty and nasal tip surgery, in particular, have evolved in the last decade to surgery characterized by tissue conservation, re-orientation and even augmentation rather than reduction. In Table 1 various nasal tip surgery techniques are listed according to their predominant conservative or aggressive nature. It is of interest to note that more aggressive techniques are described earlier than more conservative techniques and that the former are nowadays largely abandoned. This article will focus on the use of sutures for re-orientation of the medial, intermediate and lateral parts of the alar cartilages. Depending on placement and tension of the sutures, one is able to preserve or enhance nasal tip contour, projection and rotation in a controlled, graduated fashion. The basic surgical principle is similar to the one used in otoplasty for cartilage re-orientation (Mustardé, 1963) and re-positioning (Furnas, 1968). These cartilage-sparing otoplasty techniques have proven their value over time (Adamson et al., 1991; Vuyk et al., 1993). Three complementary techniques can be distin-

guished: interdomal suture (IDS), transdomal suture (TDS), and lateral crural steal (LCS). Various authors deserve credit for developing and publishing these techniques: Joseph (1932) for IDS; McCollough and English (1985) and Tardy and Cheng (1987) for TDS, and Kridel et al. (1989) for LCS. Each of these techniques has its specific indication for different nasal tip pathology. In order to clarify the concept of suture tip plasty, pertinent anatomy of the alar cartilage is briefly reviewed. The indication and technique will be described hereafter. To study the results and complications of these three complementary techniques, a series of 112 patients who underwent suture tip plasty alone or as a part of rhinoplasty, will be described.

Alar cartilage anatomy

Traditionally, alar cartilage anatomy is conceptualized as lateral and medial crura connected by a domal segment. Sheen and Sheen (1987) have divided the alar cartilages in three components: "the medial, middle and lateral crura" (cf. Figure 1). The middle crura reaches from the columellar lobule junction up till the medial border of the lateral crus and includes by definition, the additional domal segment. The middle crus can be further divided in a domal and lobular segment. Oneal et al. (1993) have described the angle of domal definition and angle of domal divergence (cf. Figure 2). Both anatomical concepts (Sheen and Sheen, 1987; Oneal et al., 1993) clarify our understanding of surgical anatomy of the nasal tip and help to understand the

* Received for publication June 15, 1993; accepted October 10, 1993

Suture tip plasty

Table 1. A list of nasal tip surgery techniques with sub-division according to nature of surgery.

| | |
|---|---|
| complete strip permanent suture cartilage overlay ¹ scoring ² cartilage grafting ³ | aggressive rim strip ⁴ lateral crural flap ⁵ vertical dome division ⁶ morselization ⁷ |
|---|---|

¹ Cartilage overlay involves a vertical division of the middle or lateral crura with subsequent overlay of both ends and suture reconstitution.

² It should be noted that deep and wide scoring may weaken the cartilage to the same degree as morselization.

³ Autogenous cartilage tip grafting is conservative in the sense that it adds strength to the nasal tip. However, the changes in contour aimed for must be controlled conspicuously.

⁴ Rim strip involved resection of the lateral most portion of the alar cartilage.

⁵ Lateral crural flap involves resection of a medial part of the lateral crura with preservation of the lateral part of the lateral crura.

⁶ Vertical dome division involves vertical transection anywhere in the domal region with or without cartilage resection and suture reconstruction.

⁷ With morselization cartilage is weakened while the volume of cartilage increases. Both changes do diminish control over this surgical manoeuvre.

concept of suture tip plasty. Part of the anatomy of the aesthetically-ideal nasal tip is formed by a concave domal segment (small angle of domal definition), and a convex lateral crus combined with a small angle of divergence (Daniel, 1987). In essence, suture tip plasty does aim to preserve, enhance or create these specific configurations.

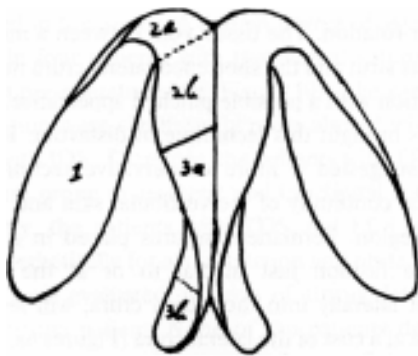


Figure 1. Base view of alar cartilages divided into three components (medial crus, middle crus, and lateral crus) and five segments. 1: lateral crus; 2a: middle crus, domal segment; 2b: middle crus, lobular segment; 3a: medial crus, columellar segment; 3b: medial crus, foot plate segment (after Daniel, 1987).



Figure 3a. A bulbous tip caused by wide interdomal distance.

Technique

The approach for nasal tip surgery depends largely on the surgeon's own preference and experience. During the past decade, the open approach has become more popular and is highly favoured by the author for its enhanced, undistorted exposure compared to endonasal approach (Vuyk, 1993; Zylker, 1993).

In order to decrease fullness in the lateral supra-tip region, a conservative volume reduction of the cephalic portion of the lower lateral cartilages will be sufficient in most patients. To prevent any distortion of the ala by scar-tissue retraction a complete strip of at least 7-8 mm in width should be maintained. By resecting a portion of the superior aspect of the lower lateral cartilages the attachment of the upper and lower lateral cartilages (being one of the major tip support mechanisms) is weakened. Subsequently, some loss of projection and some degree of rotation may occur.

In some patients a broad nasal tip remains after effective improvement of the lateral supra-tip region. A broad nasal tip is by definition analogous to a wide interdomal distance. A large interdomal distance may be caused by: (1) excessive interdomal soft tissue; (2) a broad middle crus (lobular and domal segment); and (3) a large angle of domal divergence, being similar to a bowing away from the midline of the lobular segment of the middle crura (Figure 3a). This specific anatomical situation can be improved by removing interdomal soft tissue, sometimes combined with cartilage reduction of the cephalic portion of the middle crura. The interdomal distance may be further decreased with sutures incorporating both middle crura (IDS; Figure 3b). However, a slight flaring of the caudal margins of the middle crura gives width to the infra-tip lobule which is

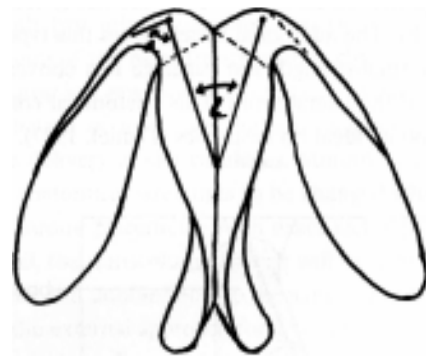


Figure 2. Alar cartilage, base view. Schematically depicted. "": tip defining point; a: angle of domal definition; b: angle of domal divergence (after Daniel, 1987).



Figure 3b. Interdomal suture (IDS) narrows the interdomal distance and refines the nasal tip.

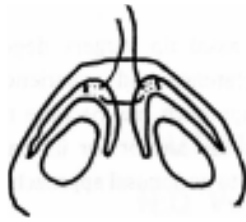

Figure 4a. A flat amorphous nasal tip due to a wide interdomal distance and a non-distinct angle between the middle and lateral crura.

natural and should be maintained. Permanent monofilament sutures, such as prolene with a buried knot, are secure and safe for this type of cartilage repositioning. Given the theoretical - but practically small - chance of suture extrusion, semi-permanent sutures with a prolonged half life of strength, such as PDS, may be used. Scar tissue will hold both domes together from 2-3 months post-operatively. Apart from improving nasal tip contour, the interdomal suture does strengthen the medial crural complex and helps to preserve nasal tip projection. Seldom, and only when combined with a columellar strut, projection may be increased by this manoeuvre. Apart from a wide interdomal distance the nasal tip may be broad, and amorphous because of a flat, non-distinct domal segment with a large angle of domal definition. Having decreased the interdomal distance with the IDS technique, attention is directed to this domal segment of the middle crus itself. A more defined, natural, smooth concave domal segment with a smaller angle of domal definition may be strived for. In order to reposition the lobular segment of the middle crura and lateral crura in a more acute angle, the flat non-distinct domal region should be transformed in a natural, smooth concave segment, creating a pleasant, well defined dome. A horizontal mattress-type permanent suture incorporating both middle and lateral crura is symmetrically positioned on both sides of the newly created dome (Figures 4a, b). The additional benefit from this type of suture in case of normal-strength alar cartilage is a convexity of the medial part of the lateral crura. This anatomical configuration may approximate ideal tip aesthetics (Daniel, 1987). Vestibular



Figure 4b. Transdomal mattress-type suture (TDS) narrowing both domes and reducing the interdomal distance.

skin dissection of the undersurface of the domal region may diminish the risk of suture extrusion. However, as long as the sutures do not penetrate the vestibular skin, vestibular skin dissection may not be essential in preventing suture extrusion. One single suture or two separate sutures may be used for both sides. The knot is tightened in a graduated fashion to achieve the degree of tip narrowing and definition aimed for. Suture tension and placement are critical for a symmetrical and anatomically satisfactory result.

A modification of this transdomal suture technique may be used if the nasal tip shape is not only broad and amorphous, but lacks projection and is rotated inferiorly. When the tripod concept of nasal tip mechanics and dynamics (Anderson and Reis, 1986) is kept in mind (Figure 5), enhanced projection follows a method that augments the combined middle and medial crural component. Superior rotation may be accomplished by shortening the lateral crura, while supporting or even lengthening (or augmenting) the middle and medial crural component. Goldman (1957) has addressed this anatomical problem by dividing the alar cartilages, including vestibular skin, while suturing both middle crura together. By planning the vertical division lateral to the domal segment of the middle crus, the medial component of the tripod was lengthened at the cost of the lateral component. This manoeuvre resulted in increased projection and superior rotation. The tissue void between a medial chondrocutaneous strut and the shortened lateral crura may result in scar contraction with a possible pinched appearance. This complication has brought this technique in disfavour. Kridel et al. (1989) has suggested a more conservative technique which maintains the continuity of the vestibular skin and cartilage in the domal region. Permanent sutures placed in a horizontal mattress-type fashion just medial to or at the dome and reaching out laterally into the lateral crura, will lengthen the middle crura at a cost of the lateral crura (Figures 6a, b). Careful dissection of the cartilage and vestibular skin facilitates suture placement and minimizes the risk of suture extrusion. The newly-formed narrow angulated segment between middle and lateral crura will lie in a more projected and upward rotated position. Both sides are addressed separately. Additional narrowing and refinement may be accomplished by interdomal and transdomal sutures. In most cases, the newly-created middle and medial crura are strengthened by an autogenous cartilage strut to maintain sufficient nasal tip support. The effect of IDS, TDS and LCS on contour, projection and rotation is schematically depicted in Table 2.

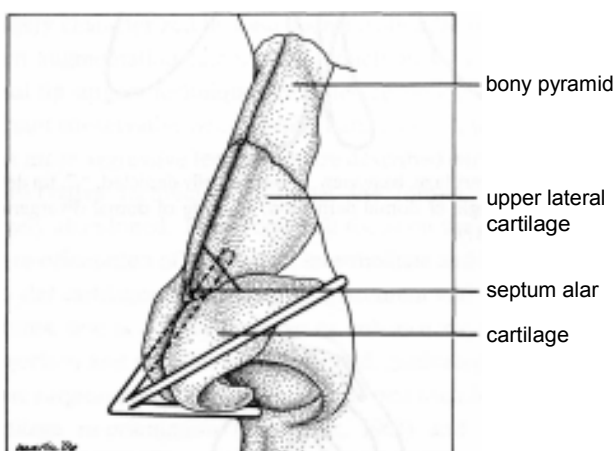


Figure 5. The alar cartilage complex is schematically represented as a tripod. Each lateral crus can be viewed as one leg of the tripod, while the conjoined medial and middle crura form the third.



Figure 6a. In case of amorphous underrotated and underprojected nasal tip, the lateral crura are moved on to the middle crura and sewn together described in the text as lateral crural steal (LCS).



Figure 6b. LCS increases projection, rotation and refines the nasal tip.

Table 2. The effect of IDS (interdomal suture), TDS (transdomal suture), and LCS (lateral crural steal) on contour, projection and rotation, schematically depicted.

| | contour | projection | rotation |
|-----|---------|------------|----------|
| IDS | ± | -* | - |
| TDS | + | ± | ± |
| LCS | + | + | + |

-: no effect; ±: possibly some effect; +: definite effect; *: preservation

PATIENTS

A series of 112 patients was studied. This series included 50 males and 62 females. The ages varied from 18 to 56, with a mean of 36 years. Follow-up varied from 2 to 52 months, with a mean of 12 months. The interdomal suture, transdomal suture and lateral crural steal has been used in 63, 37, and 12 patients, respectively.

RESULTS

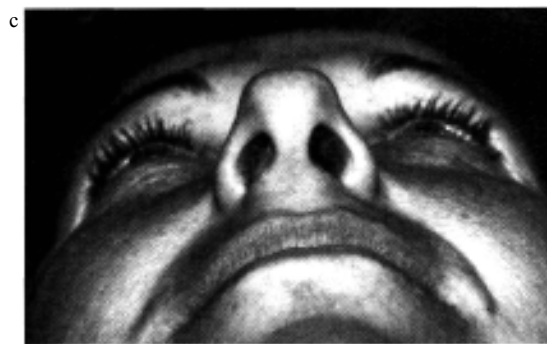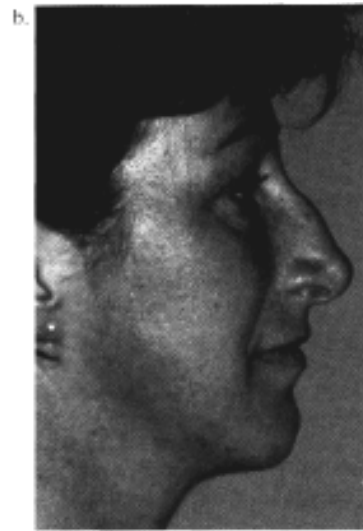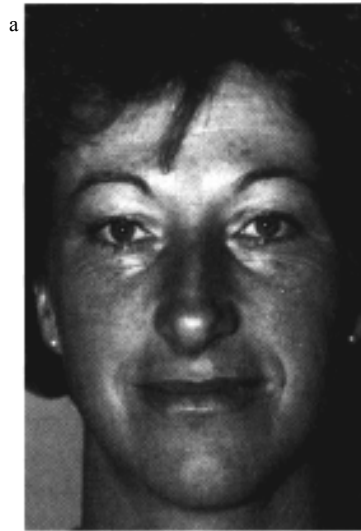In a retrospective fashion the pre- and post-operative standardized slides and patient's charts were evaluated. The overall aesthetic improvement was satisfactory. Figures 7-9 are representative for the results with the three types of suturing techniques. In three patients antibiotics were used because of post-operative swelling and redness of the nasal tip. The infection resolved completely in all three patients. Suture extrusion has not occurred in this series. A certain degree of asymmetry was noticeable in four patients with transdomal suture which was not existent pre-operatively (cf. Figure 10). Alar cartilage shape and orientation were significantly more altered with TDS and LCS than with IDS. Therefore, the patients with TDS and LCS may be more prone to aesthetic and functional complications. Subsequently, the patients with TDS and LCS were further evaluated aesthetically for alar retraction and prolapse. Functionally, they were evaluated in terms of airway deterioration as described by the patient. None of the patients demonstrated alar retraction. In one patient a small degree of alar prolapse on one side was noticeable due to insufficient suturing of the infracartilagenous incision (Figure 11). In none of the patients with TDS and LCS nasal airway was impeded by the surgical technique applied. However, in one patient the airway was not improved after surgery. This patient underwent subsequent middle third augmentation with a cartilage spreader graft for further airway improvement.

DISCUSSION

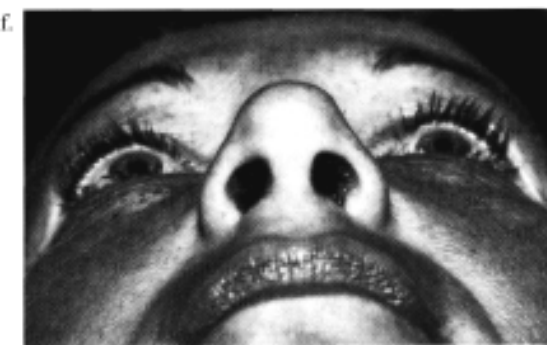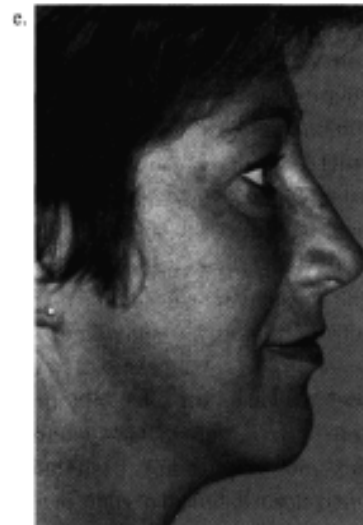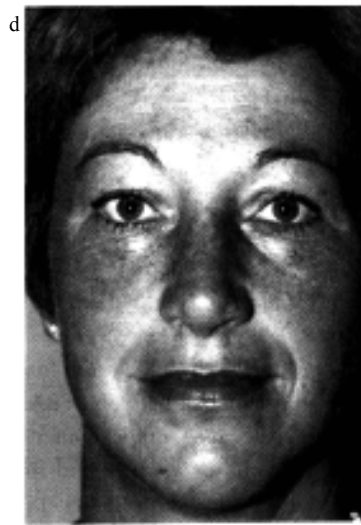Because of the vagaries of healing involved, nasal tip surgery has come away from alar cartilage-cutting techniques and

evolved into an alar cartilage-sparing type of surgery. This latter, more conservative type of surgery relies on cartilage relocation and re-orientation rather than reduction and cutting. Along the lines of these rhinoplasty developments, cartilage relocation and re-orientation can be accomplished by using (semi-)permanent sutures. Three previously described techniques, IDS (Joseph, 1932), TDS (McCullough and English, 1985; Tardy and Cheng, 1987) and LCS (Kridel et al., 1989), share in essence the same surgical philosophy. They can be considered complementary and can be applied in a graduated fashion depending on the specific nasal tip anatomy to be changed. To capture these techniques under the heading of "suture tip plasty" one underlines the technical similarity and the possible graduated application depending on the nuances in nasal tip pathology to be treated. This is analogous to "suture otoplasty" where permanent sutures have been successfully used to re-orient (Mustardé, 1963) and relocate (Furnas, 1968) ear cartilage with reproducible, satisfactory long-term results (Adamson et al., 1991; Vuyk et al., 1993). However, some problems that occur in suture otoplasty such as extrusion or asymmetry, might be possible with suture tip plasty as well. The cause of infection in a small percentage of patients was difficult to establish, regarding the multiple procedures being performed at the time of surgery. More important is the lack of suture extrusion in this series. The open approach which combines a broken, transcolumellar incision with two infracartilagenous incisions, offers tremendous exposure of the nasal tip structures which lie undistorted in their anatomical position. The exposure is even better than the combination of inter- and infracartilagenous incisions as used in the delivery of alar cartilages. Moreover, delivery does not distort the anatomical structures to be changed which may impede exact suture placement. With exact technique and attention to detail, the transcolumellar scar will be inconspicuous or hardly visible, but unobjectable to the patient. For these reasons we favour the external approach for suture tip plasty. Systematic graduated surgical correction of the broad nasal tip often starts with conservative trimming of the superior lower lateral cartilages. While keeping a complete strip of cartilage intact and preventing sharp ridges especially in the thin skin patients, contour improvement in the lateral supra-tip area may be achieved in most patients.

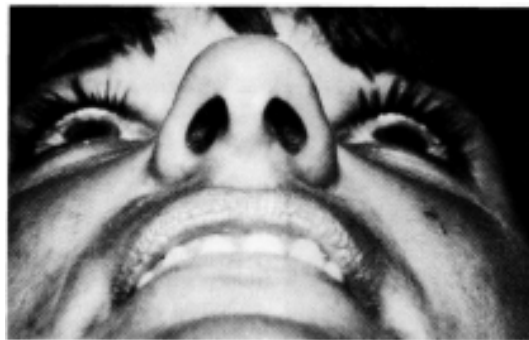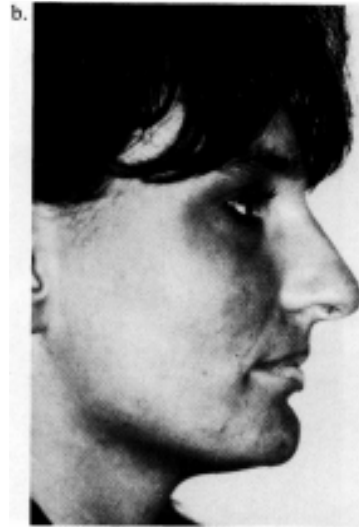When further changes to improve contour are deemed necessary one should think in terms of alar cartilage repositioning and re-shaping rather than resecting more cartilage. By resecting more cartilage a tissue void is left, which will be filled with scar tissue, leading to possible alar retraction, collapse and uncontrolled loss of nasal tip support.



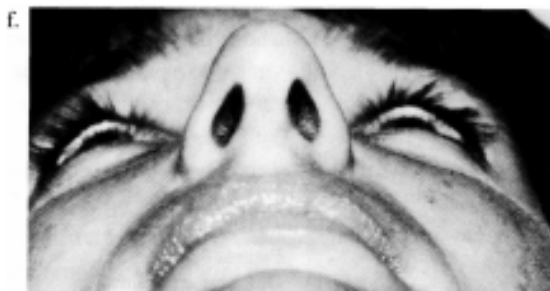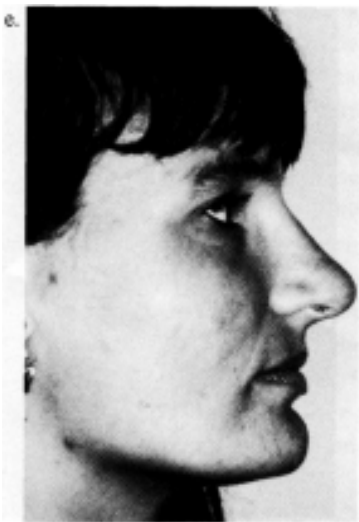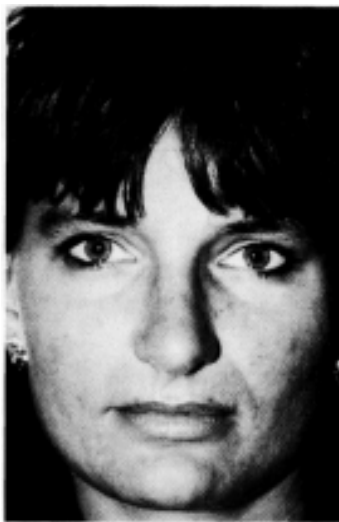Figures 7a, b, c.
A 45-year-old female with flat nasal tip.



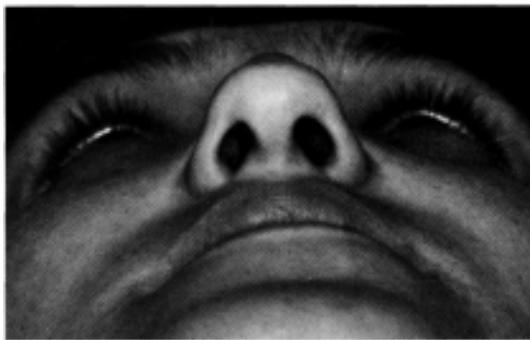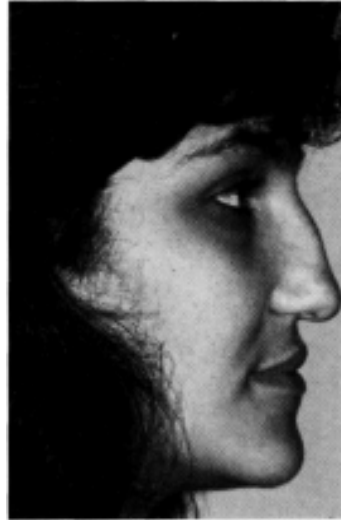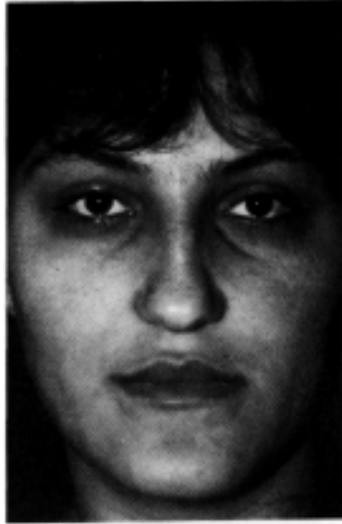Figures 7d, e, f. Two years after rhinoplasty including Interdomal suture (IDS) for tip narrowing.



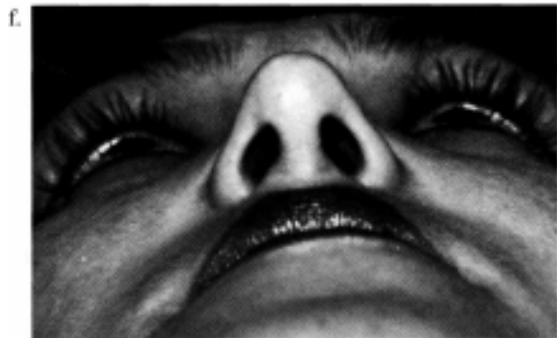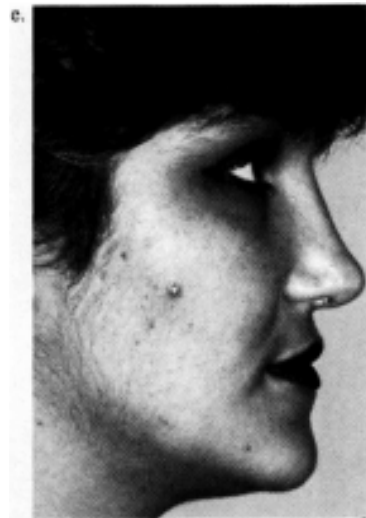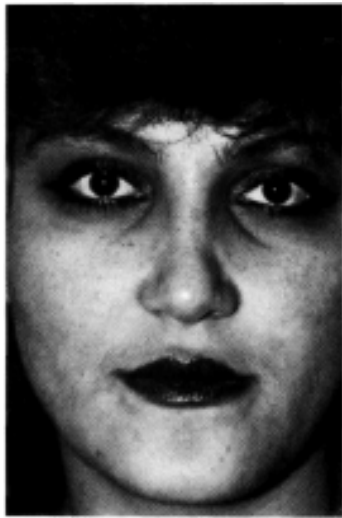Figures 8a, b, c.
A 27-year-old female with
broad amorphous nasal tip.



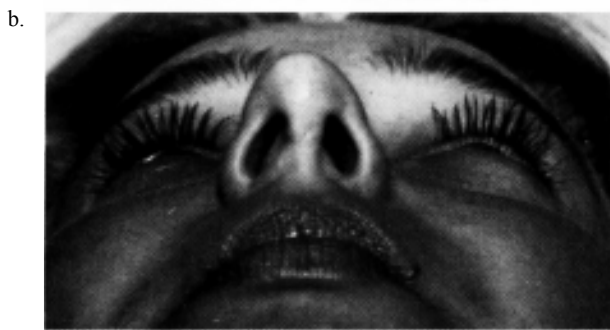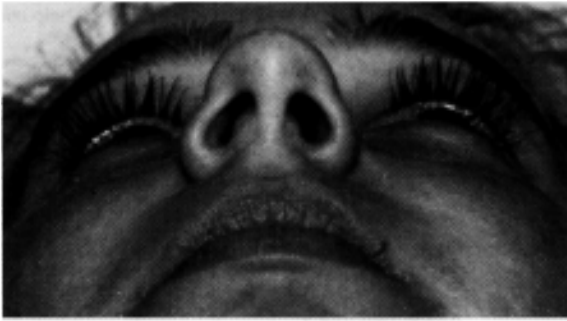Figures 8d, e, f. Seven months after
resection of cephalic portion of
lower J! lateral cartilages and
transit! domal suture (TDS).



Figures 9a, b, c.
A 30-year-old female
presenting for primary
rhinoplasty. Nasal tip under-
projection and downward
rotation can be noted.



Figures 9d, e, f.
One year after dorsal
reduction, osteotomies and
lateral crural steal (LCS).

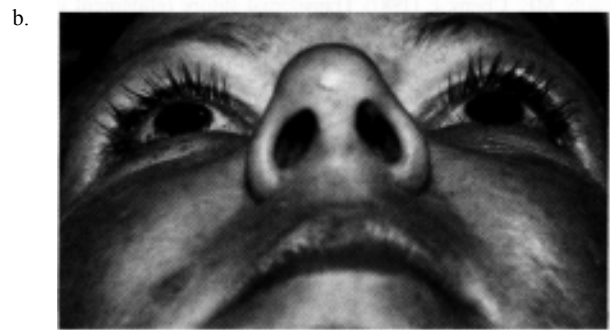
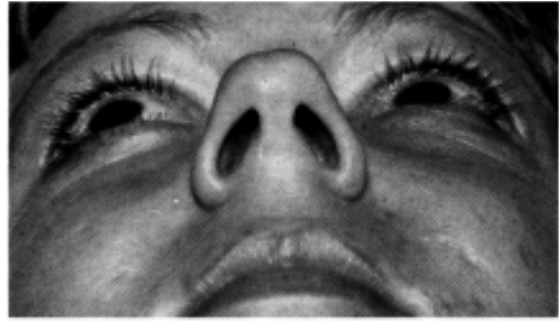
Figures 10a, b. Pre- and post-operative base view of one of the patients who has a slight asymmetry after transdomal suturing.

In this series suture extrusion has not been a problem. Monofilament sutures with buried knot are important in this respect. For the same reasons, vestibular skin dissection from the alar cartilages in the domal region is imperative if sutures are used lateral to the dome as for lateral crural steal.

The great advantage of the use of sutures for alar cartilage re-orientation and repositioning lies in the fact that at any point, the sutures used may be removed and replaced until correctly positioned and tensioned. This contrasts strongly with cartilage division, scoring or morselization techniques. The other advantage lies in the fact that suture tip plasty does not preclude the use of ancillary procedures such as cartilage scoring or autogenous cartilage grafts to the nasal tip (Zijlker and Vuyk, 1993). The asymmetry induced by TDS in some of our patients might be due to the fact that two separate sutures are used in combination with interdomal suture instead of the previously described single-suture technique (McCullough and English, 1985; Tardy and Cheng, 1987). On the other hand, the symmetric placement of one single suture through both domes proved more difficult than two separate sutures.

Narrowing of the angle between the medial and lateral crura with TDS or LCS has not led to deterioration of function. Induced aesthetic changes, such as asymmetry and alar cartilage prolapse, occur in a very small percentage of patients not needing revision surgery. Improved surgical skill will hopefully prevent these complications in the future. During our follow-up the surgical changes induced proved permanent. As in nearly every rhinoplasty, some loss of tip projection should be anticipated, this not being due to the technique involved. On the contrary, the alar cartilage tip complex is strengthened due to the sutures as well as by a columellar strut used in nearly every patient in this series. The combination of sutures and columel-



Figures 11a, b. Pre- and post-operative base view after transdomal suture in case of strong alar cartilages with slight, left alar prolapse due to insufficient suturing of infracartilaginous incision.

lar strut will, indeed, lead to minimal loss of tip projection as compared to other techniques (Petroff et al., 1991).

CONCLUSION

Suture tip plasty is presented as a combination of techniques based upon the use of sutures to induce change in alar cartilage shape and position. A range of increasing anatomic deformities can be treated when applied in a graduated fashion. Nasal tip fullness (superior lower lateral cartilage resection), broad nasal tip (IDS) without definition (TDS) and even lacking projection and rotation (LSC) can be treated with this concept. The open approach facilitates symmetric placement of sutures. This type of correction of nasal tip deformities does follow modern rhinoplasty principles and produces gratifying long-term results, while avoiding undesirable sequelae. In this series suture extrusion has not been a problem. Suture tip plasty, being a series of techniques varying in suture placement, should be part of every rhinoplasty surgeon's armamentarium.

REFERENCES

1. Adamson PA, Tropper GJ, McGraw BL (1991) Otoplasty. In: Krause (Ed.) *Aesthetic Facial Surgery*. Lippincott, Philadelphia, pp. 707-734.
2. Anderson JR, Reis WR (1986) *Rhinoplasty Emphasizing the External Approach*. Thieme, Stuttgart.
3. Daniel RK (1987) Rhinoplasty: Creating an aesthetic tip. *Plastic Reconstr Surg* 80: 775.
4. Furnas DW (1968) Correction of prominent ears by conchomastoid sutures. *Plast Surg* 42: 189-193.
5. Goldman IB (1957) The importance of the medial crura in nasal-tip reconstruction. *Arch Otolaryngol Head Neck Surg* 65: 143-147.
6. Joseph, J (1931) *Nasenplastiek und sonstigen Gesichtsplastiek nebst Mammoplastiek*. Kabitsch, Leipzig.
7. Kridel RWH, Konior RJ, Shumrick KA, Right WK (1979) Advances in nasal tip surgery. The lateral crural steal. *Arch Otolaryngol Head Neck Surg* 115: 1206-1212.

8. McCollough EG, English JM (1985) A new twist in nasal tip surgery. An alternative to the Goldman tip for the wide or bulbous lobule. *Arch Otolaryngol* 111: 524-529.
9. Mustardé JC (1963) The correction of prominent ears using simple mattress sutures. *Br J Plast Surg* 16: 170-178.
10. Oneal RM, Isenberg PH, Schlesinger J (1993) Surgical anatomy of the nose. In: RK Daniel (Ed.) *Aesthetic Plastic Surgery, Rhinoplasty*. Little, Brown and Comp., Boston, pp. 3-39.
11. PetrofTMA, McCollough EG, Hom D, Anderson JR (1991) Nasal tip projection. *Arch Otolaryngol Head Neck Surg* 117: 783-788.
11. Sheen JH, Sheen AP (1987) *Aesthetic Rhinoplasty*, 2nd Edition. Mosby, St. Louis.
12. Tardy ME, Cheng E (1987) Transdomal suture refinement of the nasal tip. *Facial Plastic Surg* 4: 317-326.
13. Vuyk HD (1993) Open rhinoplasty. Experience in 200 patients. *Rhinology* 31: 175-182.
14. Vuyk HD, Van der Baan S, Olde Kalter P (1993) Oorschelp correctie anno 1993. *Dutch Medical Journal* 13 : 664-669.
15. Zylker TD (1983b) *Open Rhinoplasty*. PhD-Thesis University of Maastricht, The Netherlands.
16. Zylker TD, Vuyk HD (1993) Cartilage grafts to the infratip lobule. *Clin Otolaryngol* 18: 446-458.

Dr. H.D. Vuyk
Dept. of Otolaryngology/Head and Neck Surgery
Gooi Noord Hospital
Rijksstraatweg 1
NL-1261 AN Blaricum
The Netherlands