

# Sub-alar batten grafts as treatment for nasal valve incompetence; description of technique and functional evaluation\*

R.F. André<sup>1</sup>, A.R. D'Souza<sup>2</sup>, H.P. Kunst<sup>2</sup>, H.D. Vuyk<sup>3</sup>

<sup>1</sup> Department of Otolaryngology / Facial Plastic Surgery, Rijnland Hospital, Leiderdorp, the Netherlands

<sup>2</sup> Fellows, European Academy of Facial Plastic Surgery

<sup>3</sup> Department of Otolaryngology / Facial Reconstructive Surgery, Gooi Noord Hospital, Blaricum, The Netherlands

## SUMMARY

**Objective:** To describe and evaluate the functional results of a surgical technique for treating nasal valve incompetence, in which a cartilage graft called a sub-alar batten graft is placed along the undersurface of the lateral crus of the lower lateral cartilage.

**Methods:** The functional outcomes of 27 patients who had sub-alar batten grafts placed on 39 sides were evaluated by means of clinical examination and subjective self-assessment.

**Results:** Of a total of 39 sides operated upon, 10 (26%) were rated as optimal, 15 (39%) as improved, 13 (33%) as equal and 1 (2%) as worse. Overall on 25 sides (65%) the post-operative situation was considered to be better than pre-operatively. In all cases in which there was a wish for cosmetic improvement, besides the functional indication, this was obtained, and in no case did the grafts give cause to cosmetic grievances or other complications.

**Conclusion:** Placement of sub-alar battens had a positive effect on nasal valve function in roughly two thirds of cases in this series. Although in our opinion this result was slightly disappointing from a purely functional point of view, they can improve the cosmetic result and continue to be considered in cases in which avoidance of surface irregularities is a primary concern or as a preventative measure in rhinoplasty patients at risk for post-operative valve collapse.

**Key words:** airway, nasal valve, nose, surgery, sub-alar batten graft

## INTRODUCTION

Nasal obstruction, frequently in combination with the desire for aesthetic improvement, continues to be one of the most common reasons for which an otolaryngologist or facial plastic surgeon is visited. Traditionally, nasal obstruction was almost considered synonymous with a septal deviation and/or inferior turbinate hypertrophy. It has become increasingly evident however, that the seemingly simple complaint of a blocked nose is often a complex clinical problem involving mucosal, structural and even psychological factors. More in particular, over the last few decades the importance of the internal and external nasal valves in maintaining nasal patency has become ever more clear. Nasal obstruction, attributable in part or entirely to a nasal valve aetiology, relates closely to the dynamics of movement of the lateral nasal wall during inspiration and to the cross-surface area, and therefore airflow resistance, of the nasal valve area. In this article we first review the concept of the nasal valve and briefly discuss some of the surgical options currently in use for treating nasal valve disorders. We then describe a technique in which a cartilage graft is placed along the under surface of the lower lateral cartilage to treat or

prevent nasal valve incompetence. We refer to this graft as a sub-alar batten and present the results of a retrospective study evaluating its effectiveness.

### Anatomy

Originally the term nasal valve described the slit like opening between the caudal end of the upper lateral cartilage and the nasal septum<sup>(1)</sup>. Since then, the term has evolved, and nowadays in the most commonly used definition an internal and an external nasal valve are described<sup>(2-5)</sup> (Figures 1, 2). The internal nasal valve is defined to be (bilaterally) located at the caudal end of the upper lateral cartilage and is formed by the angle that it makes with the nasal septum. This angle, the nasal valve angle, is normally between 10 and 15 degrees. The internal valve area is the space, which is bounded laterally by the caudal end of the upper lateral cartilage and the head of the inferior turbinate, medially by the septum and inferiorly by the floor of the nose. This is the narrowest segment of the nasal passages and accounts for most of the inspiratory airway resistance<sup>(6)</sup>. The external nasal valve includes the caudal septum, columella and premaxilla medially and the alar lobule, ala and

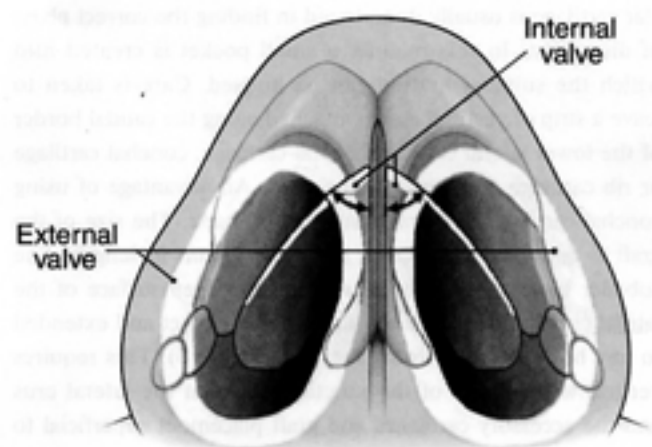


Figure 1. Internal and external nasal valve, basal view.

dilator muscles laterally<sup>(5)</sup>. The shape and strength of the external nasal valve depends on the size, shape, resilience and orientation of the lower lateral cartilages, as well as on the thickness and texture of the skin/soft tissue envelope and on the contour and position of the medial wall.

#### Function / Pathology

The internal and external valves are distinctly defined anatomically, but they show considerable functional overlap. The terms nasal valve insufficiency or incompetence are usually used to describe diminished nasal patency caused by a reduction of the internal nasal valve angle, whereas the term nasal valve collapse is generally used in cases in which the external nasal valve is sucked against the medial wall during inspiration. Although semantically separated, in reality an excessive inward movement of the lateral nasal wall usually involves elements of both valves to a varying degree.

Internal valve incompetence is often the consequence of previous reductive rhinoplasty surgery in which the attachments of the upper lateral cartilages to the septum have been severed, thereby reducing the nasal valve angle, or related to ageing where weakening of the muscular and fibrous support is apparent<sup>(7)</sup>. These patients typically demonstrate "pinching" or collapse of the supra-alar segment, which is more obvious during inspiration.

The collapse of the external valve is most often seen in patients with narrow nostrils, a projecting tip and thin weak sidewalls<sup>(8)</sup>, especially after over resection of the lateral crus of the lower lateral cartilage during rhinoplasty. Some patients demonstrate a variant anatomy involving the lower lateral cartilages, such as cephalic positioning of the lateral crura, concave lateral crura or a congenital deficiency of cartilage<sup>(9,10)</sup>.

#### Evaluation

The diagnosis can be made by observing the movement of the lateral wall during quiet and forced inspiration and by the

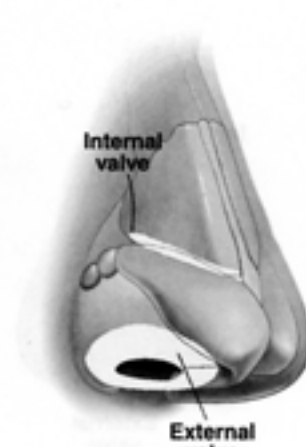


Figure 2. Internal and external nasal valve, lateral view.

diminishment of symptoms of nasal obstruction by lateralisation of the collapsed segment. This lateralisation can be done either with the classic Cottle manoeuvre which lateralises the entire lower two thirds of the nasal wall or more specifically by intranasally supporting the collapsing segment with a fine instrument<sup>(11)</sup>. Placement of a mirror handle or a Q-tip in the apex of the internal nasal valve mimicks the function of a spreader graft, which may be considered to be a good surgical option if symptoms are reduced using this test<sup>(12)</sup>.

#### Treatment

A multitude of surgical techniques have been devised for dealing with nasal valve pathology<sup>(5,7,8,10,12-30)</sup>. All such techniques have in common that they aim at strengthening and/or lateralizing (a part) of the nasal valve, thereby facilitating nasal airflow. Ideally, the choice of technique should be individualised and tailored to the exact nature of the obstruction. This is mainly based on a patient's history and subjective sensation of nasal blockage, and on the findings during physical examination. There are varying reports as to the value of objective nasal testing with acoustic rhinometry and rhinomanometry in clinical practice<sup>(31-34)</sup>. Based on our past experience, we found that the correlation between these tests and patients' subjective sense of nasal patency was too low to warrant their use for evaluating surgical results.

In cases of internal valve insufficiency, probably the most commonly used technique involves placement of spreader grafts, in the apex of the internal nasal valve<sup>(7,12,13)</sup>. Other options for internal valve insufficiency are the upper lateral splay graft<sup>(14)</sup>, upper lateral flaring sutures<sup>(15)</sup>, enlargement of the piriform aperture, by drilling the bone in the lateral and basal portion<sup>(16)</sup> or the so-called butterfly graft<sup>(17)</sup>, which because of its partial location along the (under) surface of the cephalic border of the lower lateral cartilage, probably also has a slight effect on the external nasal valve.

Various options are available to correct external valve collapse,

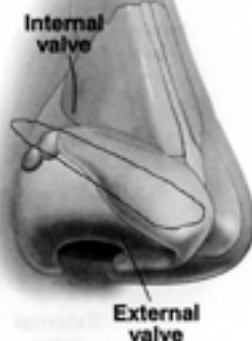

Figure 3. Right-sided sub-alar batten graft.

and in many cases these techniques will also have an effect on the internal nasal valve. Teichgraber described the use of lateral crural spanning grafts to support the area of greatest collapse<sup>(18)</sup>. Cartilage suspension techniques, either over dorsal grafts or to the infra-orbital rim, have been described to support both the upper and lower lateral cartilages<sup>(19-22)</sup>. The pinched alar deformity with a concave lateral crus can be corrected using the excised cartilage as a turnover graft<sup>(23)</sup>. External valve deformity, which involves both cartilage and vestibular skin, can be corrected with an auricular composite graft<sup>(24)</sup> and vestibular stenosis accompanied by alar base malposition can be addressed by using an alar base flap<sup>(25)</sup>. The use of alar batten grafts to correct functional deficits and to lateralise the collapsed lateral wall was reported by Toriumi<sup>(26)</sup>. Gunter described the lateral crural strut graft for treating alar rim collapse, concave lateral crura, and malpositioned lateral crura<sup>(10)</sup>. The sub-alar batten graft described in this article can be seen as a combination of the techniques described by Toriumi and Gunter. In shape (convex) and main goal (to correct and prevent nasal valve collapse by strengthening and usually lateralising the ala and/or lateral crus of the lower lateral cartilage) it closely resembles an alar batten. In position (along the undersurface of the lateral crus, instead of caudal to it) and length (from the piriform aperture to the dome, rather than just to the lateral one third of the lateral crus) it is more like a lateral crural strut graft. The reasoning and goal behind the development of this graft was to obtain the same functional result as with an alar batten, while diminishing the chance of external visibility due to its position underneath the alar cartilage<sup>(35)</sup>.

## PATIENTS AND METHODS

### Technique

Either an open or an endonasal approach may be used when placing sub-alar battens. In the open approach, after exposition of the nasal skeleton in the standard manner, the vestibular skin is meticulously dissected in a retrograde fashion off the under surface of the lateral crus. A small cephalic trim of the

alar cartilage is usually done to aid in finding the correct plane of dissection. In this manner a small pocket is created into which the sub-alar grafted can be housed. Care is taken to leave a strip of vestibular skin attached along the caudal border of the lower lateral cartilage. Septal cartilage, conchal cartilage or rib cartilage grafts may all be used. An advantage of using conchal cartilage is its inherent convex shape. The size of the graft is approximately 5 mm wide and 25mm in length. The sub-alar batten graft is positioned on the deep surface of the lateral crus in the previously undermined pocket and extended to just beyond the piriform aperture (Figure 3). This requires vertical transection of the junction between the lateral crus and the accessory cartilages and graft placement superficial to the accessory cartilages. Placement of the graft in this position helps to lengthen the distance from the nasal tip to the rim of the piriform aperture and if sutured correctly results in gentle external bowing of the lateral crus. The graft is secured to the lateral crus with two or three 6.0 PDS sutures and the pocket is closed using a 5.0 fast absorbing vicryl suture. In the endonasal approach, the sub-alar pocket is created through a marginal or rim incision through which the graft can then be inserted. The graft is secured in the same way to the lateral crus with two or three PDS 6.0 sutures and the incision closed with 5.0 fast absorbing vicryl sutures. An endonasal approach, through a rim or marginal incision, is almost always used when no additional surgery besides sub-alar batten placement is necessary.

### Patients

Between October 1996 and March 2004, 31 patients with a minimum follow-up of 3 months who had sub-alar batten grafts placed were retrospectively evaluated. Of these 31 patients, 4 were excluded (3 because of a history of cleft lip and 1 because he had lateral alar suspension sutures placed as well as sub-alar battens). This left a study group comprised of 27 patients who had sub-alar batten grafts placed on 39 sides (12 bilateral). There were 15 females and 12 males with an average age of 41 years (range 20 to 66 years). All patients had complaints of nasal obstruction caused in part at least by nasal valve incompetence and 8 of these patients also had a cosmetic indication for surgery. All patients who also had surgery for cosmetic reasons were female except one. Fourteen patients were operated on through an open approach, 13 through a closed approach. As graft material, autologous septal cartilage was utilised on 23 sides, ear cartilage on 11 sides, a combination of bone (perpendicular plate of the ethmoid) and septal cartilage on 3 sides and rib cartilage on 2 sides (in 1 patient). Nineteen patients had previously undergone cosmetic and/or functional nasal surgery. Additional procedures included a septum correction in 10 patients, spreader graft placement in 16 patients and turbinate reduction in 3 patients. In 3 patients (3 sides) no additional procedure was carried out. The minimal follow-up for this patient group was 3 months and the mean follow-up period at the time of this study was 14 months (range 3 to 53 months).

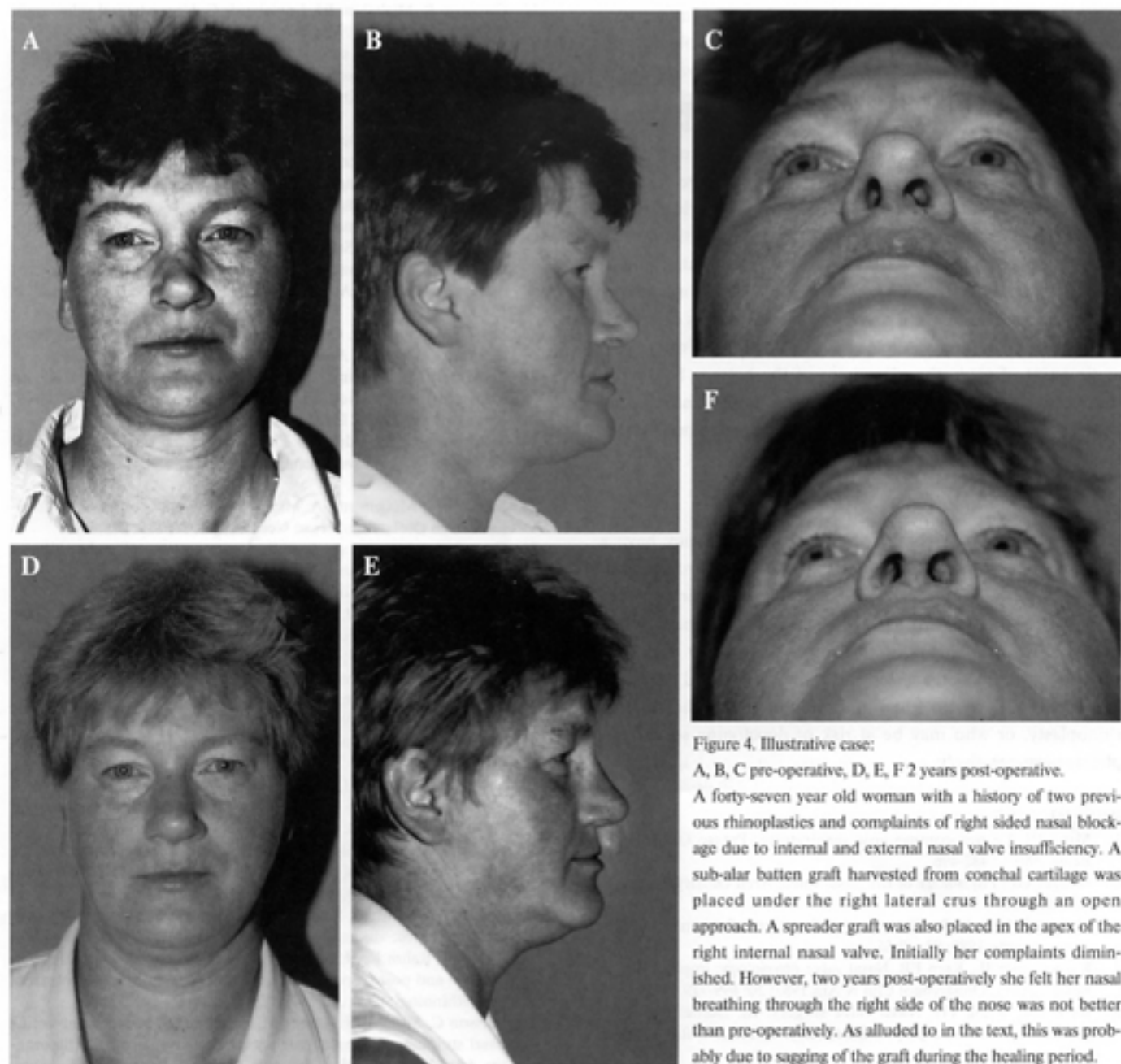


Figure 4. Illustrative case:

A, B, C pre-operative, D, E, F 2 years post-operative.

A forty-seven year old woman with a history of two previous rhinoplasties and complaints of right sided nasal blockage due to internal and external nasal valve insufficiency. A sub-alar batten graft harvested from conchal cartilage was placed under the right lateral crus through an open approach. A spreader graft was also placed in the apex of the right internal nasal valve. Initially her complaints diminished. However, two years post-operatively she felt her nasal breathing through the right side of the nose was not better than pre-operatively. As alluded to in the text, this was probably due to sagging of the graft during the healing period.

## RESULTS

All patients were examined several times during their follow-up period and were asked to rate the change in nasal patency per side comparing the post-operative to the pre-operative situation. Of a total of 39 sides operated upon, 10 (26%) were rated as optimal, 15 (39%) as improved, 13 (33%) as equal and 1 (2%) as worse. Overall on 25 sides (65%) the post-operative situation was considered to be better than pre-operatively. The one patient in whom the post-operative situation on her only operated side was worse underwent revision surgery (the original septal cartilage graft was replaced by a larger and more convex ear cartilage graft) after which the result was improved. No differences in outcome were found concerning graft material or approach used. Apart from unsatisfactory functional outcomes

no complications were noted. The patients in whom there was also an aesthetic reason for surgery were satisfied with the results and in none of the patients did the grafts cause an unsatisfactory cosmetic outcome (Figure 4).

## DISCUSSION

As with all nasal valve surgery, the primary goal of the technique presented herein is to increase the diameter and resilience of (a section of) the nasal valve. Sub-alar battens are placed along the under surface of the lateral crus, thereby supporting it and increasing its convexity. The lateral crus is located between and overlaps part of both the internal and external valve, and shows considerable variation in shape, size and strength. In this series, per- and postoperative physical exami-



nation showed that the goal of widening the cross-surface area at the level of the lateral crus had technically been obtained in a majority of patients. However the longer term overall functional improvement in this patient group (65%) was disappointing. In our opinion this probably relates partially to the fact that this technique does not, or not sufficiently, strengthen the internal valve or increase the (internal) nasal valve area. As mentioned previously, this is the area that contributes the most to nasal airway resistance. Furthermore an initial beneficial effect may be lost in the post-operative period due to sagging of the lateral nasal wall/graft complex. The second goal of this technique was to avoid un-aesthetic alar fullness or surface irregularities, and this was achieved in all patients. From a cosmetic point of view, the placement of the batten below the lateral crurae, may be preferred to more superficially placed grafts, as the latter carry an increased, if relatively unobjectionable, risk of external visibility.

## CONCLUSION

Based on this series, sub-alar batten placement may have a positive effect on nasal valve function in roughly two thirds of patients. As the batten is placed below the lateral crurae, surface irregularities can be avoided and the cosmetic result can be improved. This technique may be especially useful for patients with thin skin and long and inwardly curved weak alar cartilages, either with functional complaints at the time of rhinoplasty, or who may be at risk of developing such complaints postoperatively.

## REFERENCES

- Mink PJ. Le nez comme voie respiratoire. *Presse Otolaryngol Belge* 1903; : 482-496.
- Bridger GP. Physiology of the nasal valve. *Arch Otolaryngol* 1970; 92: 543-553.
- Haight JSJ, Cole P. The site and function of the nasal valve. *Laryngoscope* 1983; 93: 49-55.
- Kasperbauer JL, Kern EB. Nasal valve physiology: implications in nasal surgery. *Otolaryngol Clin N Am* 1987; 20: 699-719.
- Kern EB, Wang TD. Nasal valve surgery. In: Daniel RK (ed.), *Aesthetic Plastic Surgery: Rhinoplasty*. Boston: Little, Brown, 1993, pp. 613-630.
- Kimmelman CP. The problem of nasal obstruction. *Otolaryngol Clin North Am*. 1989; 22: 253-264.
- Sheen JH. Spreader graft: a method of reconstructing the roof of the middle nasal vault following rhinoplasty. *Plast Reconstr Surg* 1984; 73: 230-239.
- Toriumi 1996 Surgical correction of the aging nose. *Facial Plast Surg* 1996; 12: 205-214. Constantian MB. Functional effects of alar cartilage malposition *Ann Plast Surg*. 1993 Jun;30(6):487-99.
- Gunter JP, Friedman RF. Lateral crural strut graft: technique and clinical applications in rhinoplasty. *Plast Reconstr Surg* 1997; 99: 943-952.
- Cinelli AA. Collapse of the nares. *Arch Otolaryngol* 1971; 33: 683.
- André RF, Paun SH, Vuyk HD. Endonasal spreader graft placement as treatment for internal nasal valve insufficiency: no need to divide the upper lateral cartilages from the septum. *Arch Facial Plast Surg* 2004; 6: 36-40.
- Vuyk HD. Cartilage spreader grafting for lateral augmentation of the middle third of the nose. *Face* 1993; 3: 159-170.
- Guyuron B, Michelow BJ, Englehardt C. Upper lateral splay graft. *Plast Reconstr Surg*. 1998; 102: 2169-2177.
- Park SS. The flaring suture to augment the repair of the dysfunctional nasal valve. *Plast Reconstr Surg* 1998; 101: 1120-1122.
- Woodhead CJ. *Clin Otolaryngol Allied Sci* 1995; 20: 74-79.
- Clark JM, Cook TA. The 'butterfly' graft in functional secondary rhinoplasty. *Laryngoscope* 2002; 112: 1917-1925.
- Teichgraber JF. Lateral crural spanning grafts for the treatment of alar collapse. *Laryngoscope* 1995; 105: 760-763.
- Sciuto S, Bernardeschi D. Upper lateral cartilage suspension over dorsal grafts: a treatment for internal nasal valve dynamic incompetence. *Facial Plast Surg* 1999; 15: 309-316.
- Paniello RC. Nasal valve suspension. An effective treatment for nasal valve collapse. *Arch Otolaryngol Head Neck Surg* 1996; 122: 1342-1346.
- Lee DS, Glasgold AI. Correction of nasal valve stenosis with lateral suture suspension. *Arch Facial Plast Surg* 2001; 3: 237-240.
- Friedman M, Ibrahim H, Syed Z. Nasal valve suspension: an improved, simplified technique for nasal valve collapse. *Laryngoscope* 2003; 113: 381-385.
- McCollough EG, Fedok FG. The lateral crural turnover graft: correction of the concave lateral crus. *Laryngoscope* 1993; 103: 463-469.
- Kamer FM, McQuown SA. Minicomposite graft for nasal alar revision. *Arch Otolaryngol Head Neck Surg* 1987; 113: 943-949.
- Constantian MB. An alar base flap to correct nostril and vestibular stenosis and alar base malposition in rhinoplasty. *Plast Reconstr Surg* 1998; 101: 1666-1674.
- Toriumi DM, Josen J, Weinberger M, Tardy ME. Use of alar batten grafts for correction of nasal valve collapse. *Arch Otolaryngol Head Neck Surg* 1997; 123: 802-808.
- Constantian MB. The incompetent external nasal valve: pathophysiology and treatment in primary and secondary rhinoplasty. *Plast Reconstr Surg* 1994; 93: 919-931.
- Goode RL. Surgery of the incompetent nasal valve. *Laryngoscope* 1985; 95: 546-555.
- Stucker FJ, Hoasjo DK. Nasal reconstruction with conchal cartilage. Correcting valve and lateral nasal collapse. *Arch Otolaryngol Head Neck Surg* 1994; 120: 653-658.
- Jol JAD, Middelweerd MJ. Cartilage implants as treatment for inspiratory collapse of the lateral nasal wall and ala. *Ned. Tijdschr. KNO* 2002; 8: 149-153.
- Fisher EW, Lund VJ, Scadding GK. Acoustic rhinometry in rhinological practice: discussion paper. *J R Soc Med* 1994; 87: 411-413.
- Reber M, Rahm F, Monnier P. The role of acoustic rhinometry in the pre- and postoperative evaluation of surgery for nasal obstruction. *Rhinology* 1998; 36: 184-187.
- Larsson C, Millqvist E, Bende M. Relationship between subjective nasal stuffiness and nasal patency measured by acoustic rhinometry. *Am J Rhinol* 2001; 6: 403-405.
- Rothmann R, Chapnik J, Zamei N et al. Acoustic rhinometric assessment of the nasal valve. *Am J Rhinol* 1997; 11: 379-385.
- Tebbetts JB. Rethinking the logic and techniques of primary tip rhinoplasty: A perspective of the evolution of surgery of the nasal Tip. *Otolaryngol Clin North Am* 1999; 32: 741-754.

R.F. André, MD

Department of Otolaryngology / Facial Plastic Surgery  
Rijnland Hospital  
Simon Smitweg 1  
2353 GA Leiderdorp  
The Netherlands

Tel: +31-71-582 8051

E-mail: r.andre@rijnland.nl