



# Nasal septum perforation repair using differently designed, bilateral intranasal flaps, with nonopposing suture lines<sup>☆</sup>

R.F. André<sup>a,\*</sup>, P.J.F.M. Lohuis<sup>b</sup>, H.D. Vuyk<sup>c</sup>

<sup>a</sup>Department of Otolaryngology/Facial Plastic Surgery, Rijnland Hospital, Simon Smitweg 1, 2353 GA Leiderdorp, The Netherlands

<sup>b</sup>Department of Otolaryngology/Head and Neck Surgery, Academic Medical Center, Meibergdreef 9, 1105 AZ Amsterdam, The Netherlands

<sup>c</sup>Department of Otolaryngology, Facial Reconstructive Surgery, Gooi Noord Hospital, Rijksweg 1, 1261 AN Blaricum, The Netherlands

Received 23 December 2004; accepted 13 November 2005

## KEYWORDS

Nose;  
Septum;  
Perforation;  
Local flaps

**Summary** In this article, we briefly review the aetiology and symptoms of nasal septal perforations, and focus on a surgical reconstruction technique of which the results were retrospectively studied. The technique described, involves the interposition of a connective tissue graft between differently designed local mucoperichondrial and/or mucoperiosteal flaps on each side of the perforation, thereby preventing opposing suture lines. On one side a rotation/advancement flap is derived from the septum, the nasal floor and lateral nasal wall while in the opposite nasal passage, bipediced flaps from the septum and nasal floor and/or from the superior septum and under-surface of the upper lateral cartilage are created. Of the 43 patients included in this study, 40 had their perforation permanently closed, while three experienced a non-symptomatic recurrence. We conclude that the use of differently designed, mucoperichondrial or mucoperiosteal bilateral intranasal flaps with nonopposing suture lines, and interposition of Alloderm<sup>®</sup> or autogenous connective tissue with cartilage, especially with adequate exposure through an external approach, can lead to excellent results in the majority of cases.

© 2006 The British Association of Plastic Surgeons. Published by Elsevier Ltd. All rights reserved.

<sup>☆</sup> Presentation of technique and retrospective evaluation in 43 patients.

\* Corresponding author. Tel.: +31 71 5828282; fax: +31 71 5828918.

E-mail addresses: r.andre@planet.nl (R.F. André), p.lohuis@nki.nl (P.J.F.M. Lohuis), hvuyk@gooi-noord.nl (H.D. Vuyk).

The successful management of septal perforations often poses a significant technical challenge, and many options, both surgical and nonsurgical have been described.

Although many causes exist, the vast majority of nasal septal perforations result from trauma with

or without secondary infections. Surgical trauma during septoplasty is still one of the main offenders,<sup>1-4</sup> although less frequently so since the technique of submucous resection has largely been abandoned.<sup>5</sup> Other traumatic causes include tight nasal packing, bilateral cauterisation of nosebleeds, repeated nose picking, or inadequately treated septal haematoma with subsequent septal abscess. Various diseases, such as Wegener's granulomatosis, autoimmune disorders with vasculitis, neoplasms and rare infections such as tuberculosis and syphilis, may lie at the origin of a perforation, sometimes as the sole manifestation of such a disease. Cocaine may cause septal perforations not only due to its vasoconstrictive properties but also because of irritant additives that are often added to non-medical grade cocaine.<sup>6-8</sup>

An estimated two-thirds of perforations are either asymptomatic or cause minimal symptoms. In general, the larger and the more anteriorly located a perforation is, the more likely it is to cause symptoms,<sup>2</sup> such as crusting, nasal obstruction, rhinorrhoea, epistaxis, uncomfortable sensations while inhaling cold air and sometimes headache. Smaller perforations may lead to noisy breathing or whistling. Both nasal obstruction and crusting can be caused by excessive turbulence in the inspiratory airflow. Large perforations may seriously compromise structural support of the anterior and middle third of the nose, leading to saddling which may further impede nasal airflow.

Treatment is only necessary for symptomatic perforations and may be conservative, prosthetic or surgical. Repeated application of moistening, and when indicated, antibacterial ointments and nasal douching with saline, is sometimes all that is needed to reduce or cure symptoms of crusting and bleeding. Another option is to close the perforation by inserting a prosthetic device (usually a preformed silicone or silastic button).<sup>9</sup> A prosthesis generally needs to be cleaned and/or replaced regularly, is not well tolerated by all patients and sometimes may actually cause nasal obstruction, either because it induces increased mucus secretion and mucosal swelling or simply because of the thickness of the prosthesis.

The most important predictor of successful surgical perforation closure is the size of the perforation. The vertical height of a perforation is more critical than the anteroposterior dimensions, as the approximation of the mucoperichondrial edges from the floor of the nose to the dorsum causes the greatest tension.<sup>6</sup> A nasal septal perforation may present with a cartilaginous perforation that is considerably larger than the apparent mucosal perforation. This may severely

complicate dissection and mobilisation of mucosal flaps.

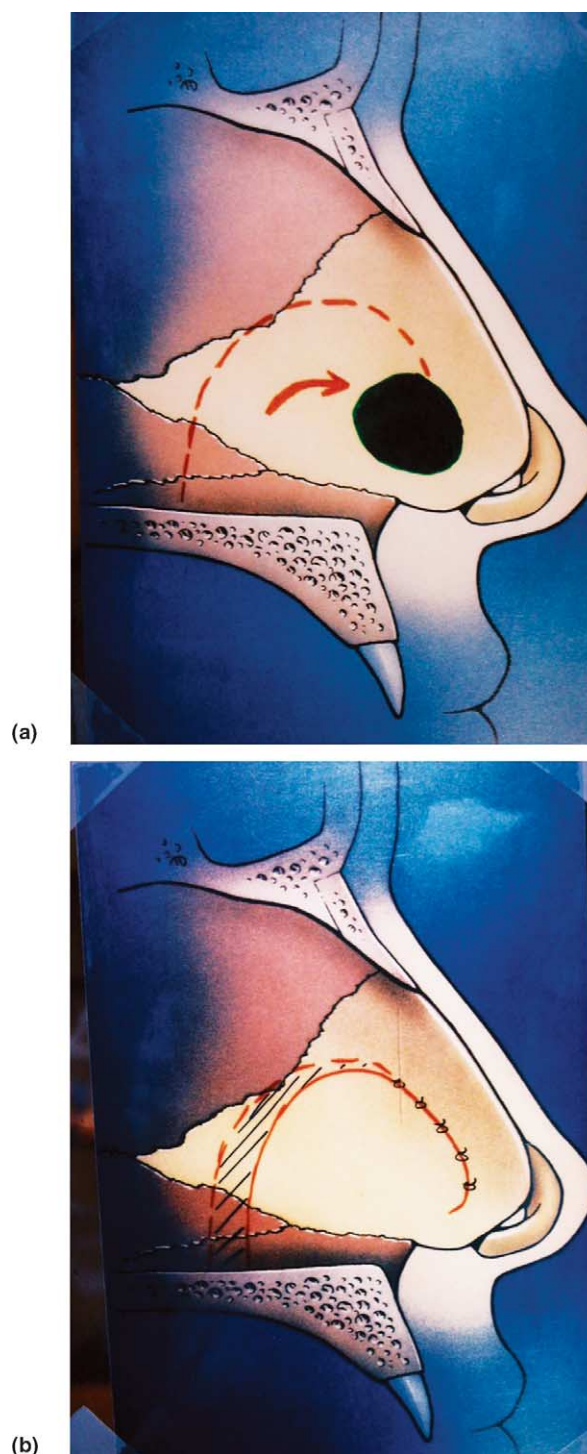
The literature describes a multitude of techniques for surgically closing a nasal septal perforation,<sup>10-27</sup> which may be a reflection of the complexity of any such surgical undertaking. To start with there is the problem of a relatively limited surgical exposure, especially through an endonasal approach. This complicates the already difficult task of separating and individually repairing each part of the three-layer architecture of the septum, necessary for the best chance of a lasting closure.<sup>1,10</sup> Matters are further complicated by a relative paucity of suitable donor material, at least regarding the respective mucoperichondrial layers. The mainstay of treatment today involves the use of local mucosal flaps with interposition of a connective tissue graft, frequently through an external rhinoplasty approach as this greatly enhances surgical exposure. An excellent review of the various techniques used for surgical septal perforation closure was published in this journal by Cogswell and Goodacre in this journal in 2000.<sup>11</sup>

## Patients and methods

Between July 1991 and June 2002, 46 patients with a septum perforation were operated upon by the same surgeon (HDV) using bilateral mucoperichondrial rotation/advancement flaps. Of these patients, three had a follow-up of less than 3 months and were excluded from the study. The average follow-up was 29 months (range 3-138 months). There were 10 women and 33 men and the average age was 36.6 years (range 16-68 years). In 14 cases the perforation was caused by previous septal surgery, in 12 cases it was due to nose picking, in three cases the cause was cocaine abuse, in two cases there had been a nasal trauma and in 12 cases no underlying cause was found. In six patients, the diameter of the perforation was smaller than 5 mm, in nine patients it was between 5 and 10 mm, in 26 patients it was between 10 and 20 mm and in two patients the diameter was larger than 20 mm. In 11 patients, a single layer of Alloderm<sup>®</sup> was used as interposition graft while in the other 32 patients ear cartilage was sandwiched between two layers of temporalis fascia. An endonasal approach was used in seven patients, in the other 36 an external approach was used, the details of which will now be described insofar as they pertain to this specific procedure.

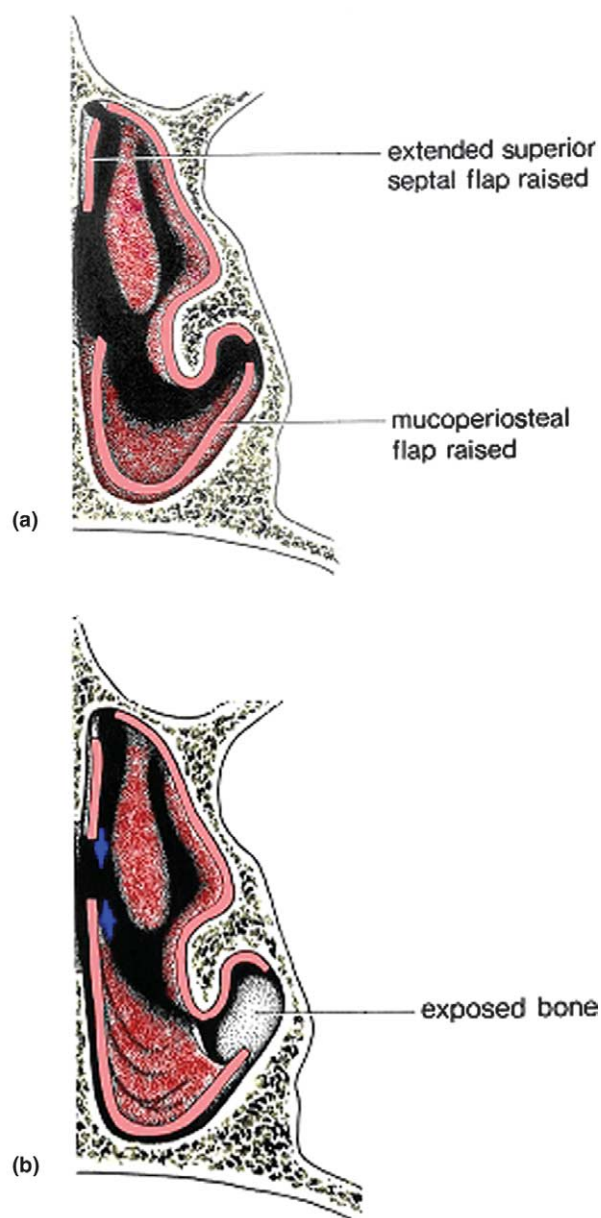
The first step of the operation is to incise the intranasal flap margins using a rigid 0-degree

nasendoscope and a specially bent and hooked (Beaver) knife. Subsequently, a mid-columellar broken line skin incision is connected with bilateral marginal incisions as for a standard external approach. The nasal skin is carefully elevated from the underlying nasal skeleton in the supraperichondrial plane. The caudal edge of the cartilaginous septum is exposed after complete division of the intermedial crural and interdomal ligaments. The upper lateral cartilages are dissected from the dorsal edge of the septum on both sides. Subsequently, bilateral mucoperichondrial flaps are elevated from the septum and extended around the perforation. The goal of mucosal flap mobilisation is to close the defect completely on both sides, while avoiding opposing suture lines and maintaining adequate blood supply. Different designs of mucoperichondrial flaps are used on each side of the perforation to prevent opposing suture lines. On one side a rotation/advancement flap is derived from the septum, the nasal floor and lateral nasal wall Fig. 1. Mucoperichondrium dissected from the septum is extended in continuity with the mucoperiosteum of the floor of the nose and up the lateral wall until the attachment of the inferior turbinate. In larger perforations (bigger than 2.5 cm), the rotation flap is designed to include lateral and/or medial mucosa from the inferior turbinate. These rotation flaps are mostly based anteriorly on the branches of the superior labial artery.<sup>24</sup> This is preferable to posteriorly based mucoperiosteal flaps that are often too short to reach an anterior septal perforation.<sup>8</sup> In the opposite nasal passage, bipediced flaps from the septum and nasal floor are developed<sup>6,22</sup> and usually a superior mucoperichondrial bipediced septal flap is also created Fig. 2. Sometimes mucoperichondrium from the under-surface of the upper lateral cartilage is included or alternatively a cut may be made in the mucoperichondrium at the junction of the septum and upper lateral cartilage, creating a bipediced flap to advance inferiorly.<sup>23,28</sup> If a concomitant reduction rhinoplasty is indicated, lowering of the nasal dorsum will help to create a relative excess of mucoperichondrium to be used for perforation closure.<sup>29</sup> Occasionally, a perforation cannot be closed completely on one or both sides and the connective tissue interpositional graft can serve as a template for migration of the overlying healing flaps.<sup>23,30</sup> The mucosal flaps are approximated, using nontraumatic forceps, and sutured without tension with multiple fast absorbable 5/0 Vicryl® sutures. Autogenous fascia and/or periosteum are obtained through a high postauricular temporal skin incision. Thickness depends on whether superficial temporalis fascia, loose areolar tissue or deep



**Figure 1** (a) and (b) An inferoanteriorly based rotation/advancement mucoperichondrial flap.

temporalis fascia is taken.<sup>31</sup> The connective tissue grafts are placed under the mucoperichondrial flaps on both sides of the septum and should ideally overlap the defect on all sides. Subsequently, the cartilaginous and bony defect is reconstructed with auricular autogenous cartilage, which should fit precisely. Alternatively one layer of acellular



**Figure 2** (a) and (b) Bipedicled, anteriorly and posteriorly based superior and inferior advancement flaps.

human dermal allograft may be inserted, obviating the need for harvesting of additional autogenous temporalis fascia and ear cartilage. After insertion of the grafts, tissue adhesive (fibrin glue) may be used to secure and stabilise the reconstructed area. Nasal septal splints are secured with horizontal mattress sutures. The upper lateral cartilages are sutured back to the septum. The advice to refrain from alloplastic material insertion for dorsal augmentation when possible, gains even more importance than usual because of the proximity and size of intranasal wounds.<sup>32</sup> Marginal and columellar incisions are closed with interrupted sutures. A nonadherent absorbing

dressing is applied for 24 h. The nose is taped and a cast applied for 1 week. The splints are usually left in place for 2-3 weeks. The nose is kept moist with nasal douches, using saline solution and ointment. Broad-spectrum antibiotics are administered 1 h before the operation and continued for 7 days.

## Results

At a minimum of 3 months all patients were re-examined although the majority had a much longer follow-up period. Of the 43 patients included in this study, 40 (93%) had their perforation permanently closed, while three (7%) had a recurrence. In two of these three patients, the size of the recurrence was less than 10% of the original perforation. In the third patient, the perforation was roughly half the original size. All three patients remained symptom free and did not need a second operation. In general, unsuccessful closure or a recurrence may occur because of poor exposure, inadequate mobilisation of mucoperichondrial flaps, closure under tension and/or because of poor approximation of septal flaps.<sup>33</sup> Except for age (all three patients with a recurrence were over 50), no common variable concerning the sex of the patient, the aetiology, the size of the perforation, the surgical approach or the type of interposition graft was found. A few patients developed minor synechia along the nasal floor or roof but these had no functional significance. In patients with large septal perforations that required mucosal mobilisation from the inferior turbinate, epiphora is a theoretical complication but did not occur in our study.<sup>8</sup>

## Discussion

The mucoperiosteal and perichondrial flaps described are broadly based random flaps (inferoanteriorly based septal rotation/advancement flaps Fig. 1 as well as superior and inferior bipedicled advancement flaps, anteriorly and posteriorly based Fig. 2), or axial flaps containing a named artery (anteriorly based, narrow pedicled, transposition or rotation flap based on a branch of superior labial artery). The use of mucoperichondrial flaps conforms to Gillies' principle that tissue loss must be replaced by the same kind of tissue.<sup>34</sup> The non-juxta positioning of the flaps prevents opposing suture lines and avoids jeopardising the intervening septal cartilage/bone in case one of the

flaps fails to heal. Dissection of flaps, especially out of the maxillary crest/nasal floor transition zone should be done with care to prevent flap tears. A septal deviation or winged maxillary crest may make dissection particularly difficult. It is doubtful whether dissection of the flap out of the bony tunnel of the anterior palatine neurovascular bundle, which sacrifices the anterior palatine vascular supply, will increase flap mobility. It may, in fact, lead to a higher risk of flap necrosis. When unilateral failure occurs, this may not be detrimental to the reconstruction as the other vital mucosal flap supports the healing by secondary intention of the opposite failed flap. One publication does support this notion by suggesting the use of a unilateral mucosal flap and temporalis fascia only.<sup>30</sup> The use of large intranasal mucosal flaps necessarily leads to large denuded areas. Non-epithelialised areas heal secondarily with proper treatment without long-term dryness or crusting, comparable to Caldwell Luc cavities. The above-described intranasal flaps are preferred to tunnelled buccal mucosal flaps as these may lead to scarring and/or oronasal fistulas, sometimes needing repair.<sup>12</sup> However, for successful closure of very large perforations (larger than 2.5 cm), a three-staged procedure using a cartilage reinforced buccal flap may be indicated.<sup>17</sup> Tissue expansion is a theoretically attractive proposition, and has been described to increase the dimension of the intranasal flap.<sup>35</sup> Another key aspect is the utilisation of low-metabolic fascia/periosteal interposition grafts as scaffolding for epithelialisation. The use of autogenous cartilage lends strength and durability to the reconstructed septum. Only rarely does the width of the reconstructed septum appear to impair nasal breathing. The disadvantage of autogenous graft harvesting includes additional operative time and postoperative morbidity. Moreover, temporalis fascia is thin and technically difficult to manage. Kridel has championed the use of acellular human dermal allograft (Alloderm®) as an alternative interposition graft.<sup>23</sup> A layer of 1-mm thickness Alloderm® interposition graft seems to be a reasonable alternative to autogenous grafts in terms of cost-effectiveness, patient friendliness and success rate.<sup>23</sup>

The technique presented herein, for the surgical closure of nasal septal perforations, combines several components of previously described techniques, and uses recognised surgical principles. Although this technique may not be adequate for very large perforations, and is not always necessary for smaller ones, for the majority of septal perforations it is our procedure of choice. The use of highly vascularised mucoperichondrial and mucoperiosteal intranasal

flaps with interposition of Alloderm® or autogenous connective tissue for epithelialisation and cartilage for support aims at a complete anatomic closure. Though no method ensures 100% success, the use of differently designed contralateral flaps with non-opposing suture lines, tension-free closure and adequate exposure, especially through an open approach, greatly enhances the surgical results of this challenging problem.

## References

1. Fairbanks DN, Fairbanks GR. Nasal septal perforation: prevention and management. *Ann Plast Surg* 1980;**5**(6): 452-9.
2. Brain DJ. Septo-rhinoplasty: the closure of septal perforations. *J Laryngol Otol* 1980;**94**(5):495-505.
3. Pallanch JF, Facer GW, Kern EB, Westwood WB. Prosthetic closure of nasal septal perforations. *Otolaryngol Head Neck Surg* 1982;**90**(4):448-52.
4. Vuyk HD, Versluis RJ. The inferior turbinate flap for closure of septal perforations. *Clin Otolaryngol* 1988;**13**(1):53-7.
5. Huizing EH, de Groot JA. *Septal perforation. Functional reconstructive nasal surgery*. Stuttgart: Georg Thieme Verlag; 2003 p. 180-8.
6. Kridel RW, Foda H. Nasal septal perforation: prevention, management, and repair. In: Papel ID, editor. *Facial plastic and reconstructive surgery*. 2nd ed. New York: Georg Thieme Verlag; 2002. p. 473-81 [chapter 41].
7. Fairbanks DN. Nasal septal perforation repair: 25 year experience with the flap and graft technique. *Am J Cosmet Surg* 1994;**11**:189/194.
8. Teichgraeber JF, Russo RC. The management of septal perforations. *Plast Reconstr Surg* 1993;**91**(2):229-35.
9. Facer GW, Kern EB. Nonsurgical closure of nasal septal perforations. *Arch Otolaryngol* 1979;**105**(1):6-8.
10. Younger R, Blokmanis A. Nasal septal perforations. *J Otolaryngol* 1985;**14**(2):125-31.
11. Cogswell RK, Goodacre TEE. The management of nasoseptal perforation. *Br J Plast Surg* 2000;**53**(2):117-20 [review].
12. Rettinger G, Masing H, Heinel W. Management of septal perforations by rotationplasty of the septal mucosa. *HNO* 1986;**34**(11):461-6.
13. Karlan MS, Ossoff R, Christu P. Reconstruction for large septal perforations. *Arch Otolaryngol* 1982;**108**(7):433-6.
14. Gollom J. Perforation of the nasal septum. The reverse flap technique. *Arch Otolaryngol* 1968;**88**(5):518-22.
15. Arnstein DP, Berke GS. Surgical considerations in the open rhinoplasty approach to closure of septal perforations. *Arch Otolaryngol Head Neck Surg* 1989;**115**(4):435-8.
16. Murakami CS, Kriet JD, Ierokomos AP. Nasal reconstruction using the inferior turbinate mucosal flap. *Arch Facial Plast Surg* 1999;**1**(2):97-100.
17. Meyer R. In: Conley J, Dickinson JT, editors. *Plastic and reconstructive surgery of the face and neck*. New York: Grune and Stratton; 1972. Meyer R. Total nasal reconstruction. In: Conley JJ, Dickinson JT, editors. *Plastic and reconstructive surgery of the face and neck: proceedings of the first international symposium*. Stuttgart: Georg Thieme Verlag; 1972.
18. Fairbanks DN, Fairbanks GR. Surgical management of large nasal septum perforations. *Br J Plast Surg* 1971;**24**(4):382-7 [PMID: 5115041, PubMed-indexed for MEDLINE].

19. Fairbanks DN. Closure of nasal septal perforations. *Arch Otolaryngol* 1980;106(8):509-13.
20. Kridel RW, Appling WD, Wright WK. Septal perforation closure utilizing the external septorhinoplasty approach. *Arch Otolaryngol Head Neck Surg* 1986;112(2):168-72.
21. Zijlker TD, Vuyk H. Cartilage grafts for the nasal tip. *Clin Otolaryngol* 1993;18(6):446-58.
22. Schultz-Coulon HJ. Experiences with the bridge-flap technique for the repair of large nasal septal perforations. *Rhinology* 1994;32(1):25-33.
23. Kridel RW, Foda H, Lunde KC. Septal perforation repair with acellular human dermal allograft. *Arch Otolaryngol Head Neck Surg* 1998;124(1):73-8.
24. Karlan MS, Ossoff RH, Sisson GA. A compendium of intranasal flaps. *Laryngoscope* 1982;92(7 Pt 1):774-82.
25. Romo III T, Foster CA, Korovin GS, Sachs ME. Repair of nasal septal perforation utilizing the midface degloving technique. *Arch Otolaryngol Head Neck Surg* 1988;114(7):739-42.
26. Kridel RW, Appling D, Wright W. Closure of septal perforations: a simplified method via the external septorhinoplasty approach. In: Ward P, Berman W, editors. *Plastic and reconstructive surgery of the head and neck: proceedings of the fourth international symposium, Los Angeles, 1983*, vol. 1. St Louis: CV Mosby Co.; 1984. p. 183-8.
27. Vuyk HD, Olde Kalter P. Open septorhinoplasty. Experiences in 200 patients. *Rhinology* 1993;31(4):175-82.
28. Ingels K. External rhinoplasty for the closure of medium sized septum perforations. *Ned Tijdschr KNO-Heelk* 1999;5(2):46/53 [article in Dutch].
29. Strelzow VV, Goodman WS. Nasoseptal perforation—closure by external septorhinoplasty. *J Otolaryngol* 1978;7(1):43-8.
30. Mina MM, Downar-Zapolski Z. Closure of nasal septal perforations. *J Otolaryngol* 1994;23(3):165-8.
31. Vuyk HD, Adamson PA. Biomaterials in rhinoplasty. *Clin Otolaryngol* 1998;23(3):209-17.
32. Godin MS, Waldman SR, Johnson Jr CM. Nasal augmentation using Gore-Tex. A 10-year experience. *Arch Facial Plast Surg* 1999;1(2):118-21 [discussion 122].
33. Kridel RW. The open approach for repair of septal perforations. In: Daniel RK, editor. *Aesthetic plastic surgery: rhinoplasty*. Boston: Little, Brown and Company; 1993. p. 555.
34. Gillies H, Millard DR. *The principles and art of plastic surgery*. Boston: Little, Brown and Company; 1957 p. 50-4.
35. Romo III T, Jablonski RD, Shapiro AL, McCormick SA. Long-term nasal mucosal tissue expansion use in repair of large nasoseptal perforations. *Arch Otolaryngol Head Neck Surg* 1995;121(3):327-31.